



The Resolution of Hypertension after Adrenalectomy in Patient with Aldosterone-Producing Adenoma

Rania Alsayed Murad¹, Ashraf Alakkad^{2*}, Fadi Almahameed³,
Mohamed Wahba⁴ and Anmar Hakki⁵

¹Department of Endocrinology, Madinat Zayed Hospital, UAE.

²Department of Internal Medicine, Madinat Zayed Hospital, UAE.

³Department of General Surgery, Madinat Zayed Hospital, UAE.

⁴Department of Anesthesia, Madinat Zayed Hospital, UAE.

⁵Department of Radiology, Madinat Zayed Hospital, UAE.

Authors' contributions

This work was carried out in collaboration among all authors. All authors read and approved the final manuscript.

Article Information

Editor(s):

(1) Dr. Prabakaran Nagarajan, The Ohio State University, USA.

Reviewers:

(1) Gurdeep Singh, Our Lady of Lourdes Memorial Hospital, USA.

(2) Stanislav Alexandra Alina, County Emergency Hospital, Romania.

Complete Peer review History, details of the editor(s), Reviewers and additional Reviewers are available here:
<https://www.sdiarticle5.com/review-history/77172>

Case Study

Received 11 September 2021

Accepted 23 November 2021

Published 30 November 2021

ABSTRACT

A 52-year-old patient from Bangladesh, known for hypertension for the last year, was taking oral antihypertensives. Nonetheless, he still had uncontrolled blood pressure, and no associated symptoms. The patient was referred to Emergency with a presenting complaint of high blood pressure, and high aldosterone and low renin levels. Therefore, a subsequent work-up plan was recommended for him.

As per the lab reports, the patient was found to be suffering from primary aldosteronism. This was concluded by looking at his lab values, which were seen to be as follows: Aldosterone: 320 ng/L, Renin: 2.55 ng/L, Potassium: 5.2 mmol/L. An MRI of the adrenal gland was ordered for this patient, both with and without contrast. The findings of the MRI were consistent with left adrenal adenoma. An approximately 14 x 10.4 x 10.8 mm, oblong-shaped focal lesion, along the maximum TS, AP, and CC dimensions was appreciated. This lesion was implicating the inferior portion of the left adrenal gland lateral limb, and exhibiting low to intermediate signal intensity on all provided

*Corresponding author: E-mail: ashraf.alaqqad@gmail.com;

sequences with signal dropout on out of the phase sequence. Moreover, minimal peripheral contrast enhancement was noted in the post-contrast administration images.

This led to a prompt referral to the surgery department where the patient was evaluated and, within a week, operated on for the tumor successfully.

This paper deals with the evaluation, diagnosis, and postoperative management of this patient who arrived at the hospital with no suspicion of the tumor that he had in his adrenal glands. Finally, it also summarizes the post-operative symptoms experienced by the patient and how they were managed on the spot to prevent any ensuing complications.

Keywords: Primary aldosteronism; hypertension; adrenal glands.

1. INTRODUCTION

The adrenal glands or 'suprarenal glands' are small yet highly important, triangular glands that are part of the endocrine system. They are located at the top of each kidney and are found to play an important role in the fight or flight system of an individual as they work to reduce stress hormones under the appropriate stimulus to help the body deal with several pressurized conditions. Apart from this, the adrenal glands also secrete other hormones that are involved in the regulation of the body's metabolism, water and salt balance, and immunity building [1].

It is because of these important and dependent roles that the normal functioning of the adrenal glands is considered necessary. However, there are several benign lesions that may occur in relation to the adrenal glands and which can then alter their normal functioning. In the long term, these lesions may cause unwanted symptoms in the body of the affected individual, thus raising suspicions that require proper evaluation to be remedied [2].

Any pathologies that arise within the adrenal glands firstly give rise to endocrine hypertension. Since a patient might already be suffering from primary, or 'essential', hypertension, it is called 'secondary hypertension' when the hypertension is documented to arise secondarily to an adrenal gland pathology.

The mere presence of hypertension in a patient might make it difficult for them to be diagnosed or evaluated for an adrenal gland disorder since hypertension is commonly diagnosed in patients. However, there are several other symptoms that differentiate the root causes of hypertension. In most cases of secondary hypertension, primary aldosteronism is the cause [3-5].

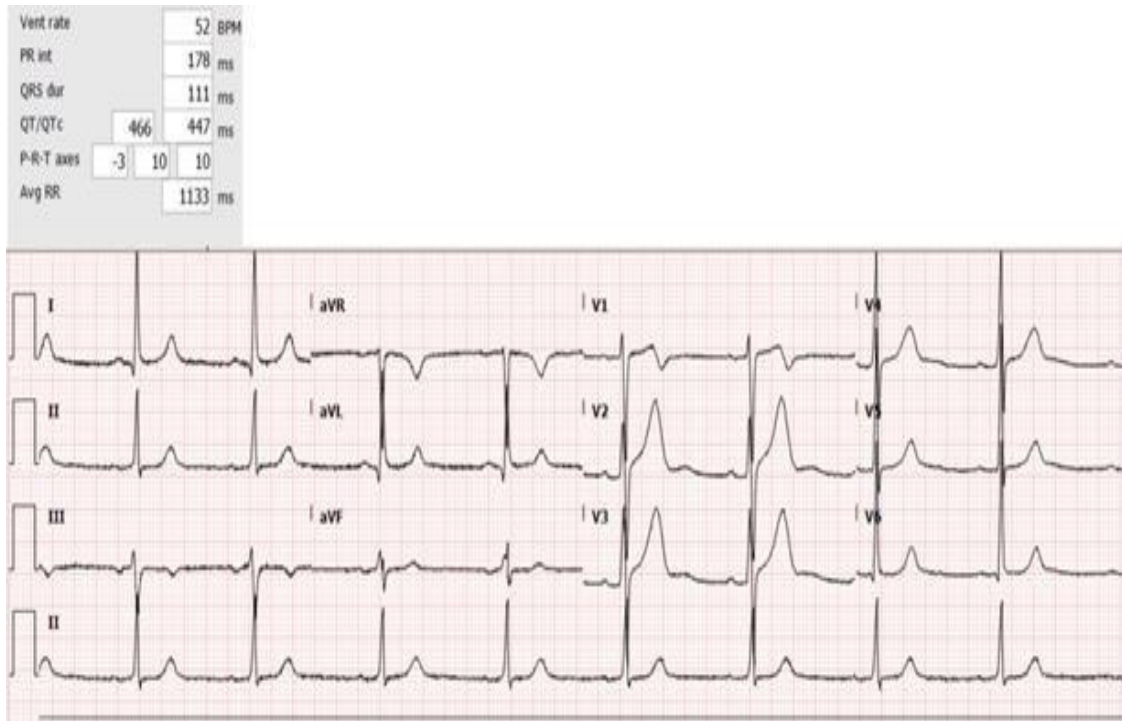
This patient mimicked this exact scenario. He had no initial complaint except for uncontrolled blood pressure, which is often seen in patients who have are later diagnosed with this problem. It was only a matter of a timely and acute diagnosis that convinced the doctors that the adrenal glands were involved in this case. As a result, the appropriate investigations lead to the prompt diagnosis of an adrenal adenoma in the patient, which as treated on time, thus saving the patient's life.

2. CASE STUDY

A 52-years old patient from Bangladesh was presented to the hospital. About a year ago, he had been diagnosed with hypertension and started an oral antihypertensive regimen of Amlodipine/Telmisartan at a dose of 10 mg/80 mg. Now, a year later, he was still experiencing uncontrolled blood pressure. It remained on the higher side despite taking regular antihypertensives, but there were no other common alarming factors, such as headache, vomiting, or blurring of vision. The patient's lab workup revealed that he was suffering from primary hyperaldosteronism. When he was referred to the hospital he had high aldosterone levels with low renin levels, along with persistently elevated blood pressure levels. Therefore, for further evaluation and to reach a proper diagnosis, the patient was sent to get an MRI of his adrenal gland, both with and without contrast.

2.1 Investigations

The study deals with the evaluation, diagnosis, and postoperative management of the patient who arrived at the hospital with no suspicion of the tumor that he had in his adrenal glands.



Pic. 1. The following investigations and lab work-ups were ordered

Table 1. Laboratory results

Event	Result	Ref. Range	Status
Cortisol AM	380 nmol/L	(171 - 536)	
TV Catechol Fract	2.180 L		
Ur Dopamine	* 405 nmol/L		
Ur Epinephrine	< 10 nmol/L		
Ur Norepineph	84 nmol/L		
U24 Dopamine	* 883 nmol/24 hrs	(- <= 3240)	
U24 Epinephrine	* < 22 nmol/24 hrs	(- <= 150)	
U24 Norepineph	* 183 nmol/24 hrs	(- <= 570)	
TV Metanephrines	2.180 L		
Ur Metanephrine	* 138 nmol/L		
U24 Metanephrine	301 nmol/24 hrs	(- <= 2000)	
Surgical pathology Final Report	* 02-SP-21-0010441		
Sodium Lvl	* 139.0 mmol/L	(135.0 - 145.0)	
Potassium Lvl	* 5.2 mmol/L	(3.6 - 5.1)	
Chloride Lvl	* 106.0 mmol/L	(98.0 - 107.0)	
CO2	* 24.7 mmol/L	(22.0 - 29.0)	

Table 2. Laboratory results

Event	Result	Ref. Range	Status
Aldost Standing	* 320.00 ng/L	(50.50 - 310.50)	
Renin Act (std)	* 2.55 ng/L	(4.00 - 37.52)	
Aldosterone/Renin Ratio (Standing)	* 125.49		
ARR (standing) Pathologist comment	ARR (standing) Pathologist comment		
Aldost Supine	* 308.50 ng/L	(28.80 - 158.60)	
Renin Act (sup)	* 2.80 ng/L	(4.00 - 23.70)	
Aldosterone/Renin Ratio (Supine)	* 110.18		
ARR (supine) Pathologist comment	ARR (supine) Pathologist comment		
Potassium Lvl	* 3.2 mmol/L	(3.6 - 5.1)	

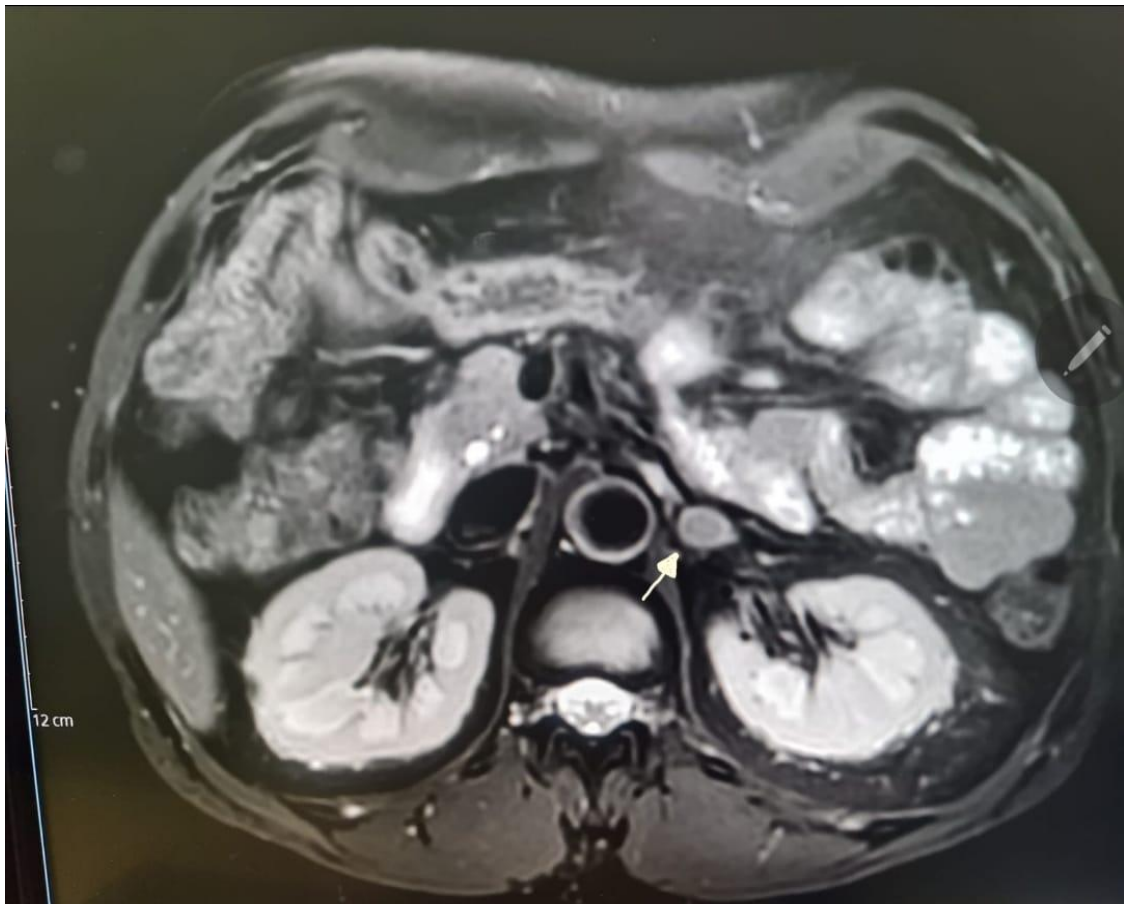


Fig. 1. These MRIs of the patient were obtained

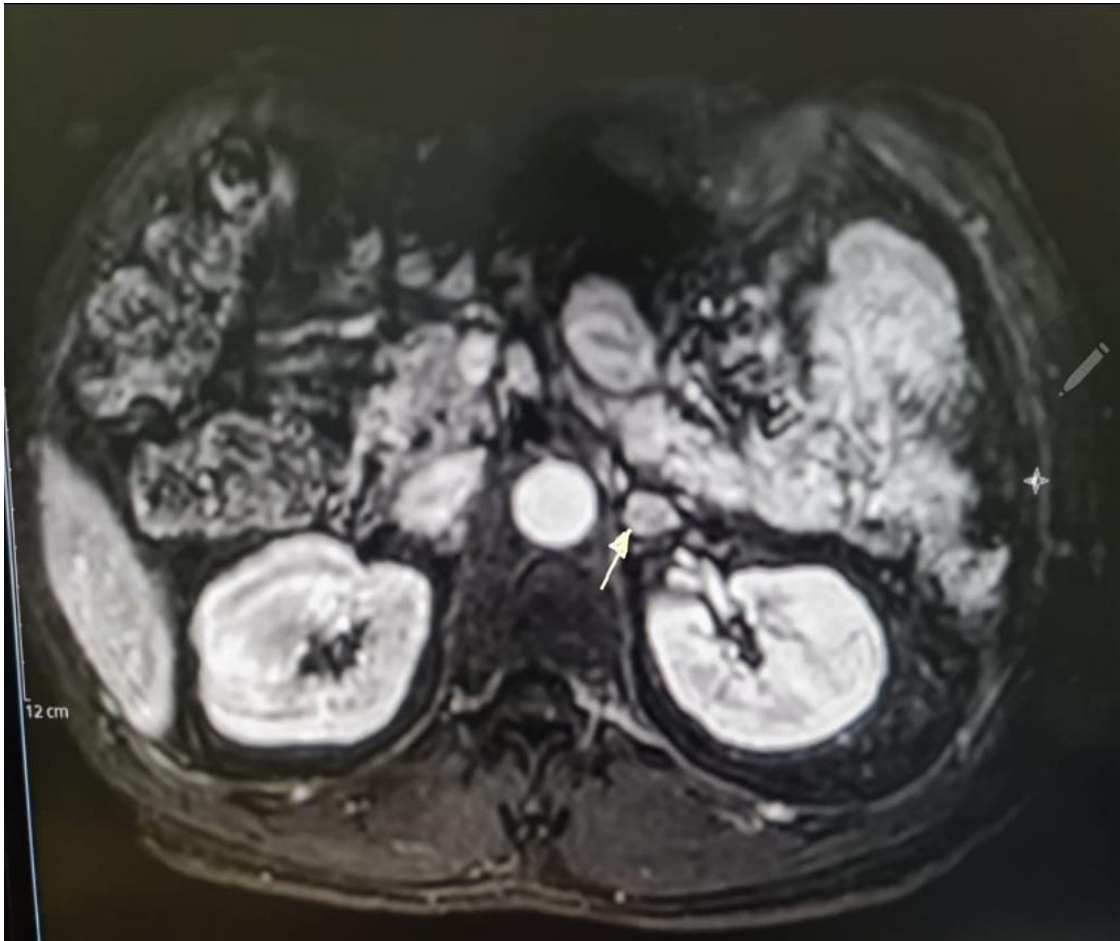


Fig. 2. MRI scan image

2.2 Findings

According to the above MRI scans, the patient was found to be harboring an approximately 14 x 10.4 x 10.8 mm fairly-defined, oblong-shaped focal lesion, along the maximum TS, AP, and CC dimensions. This lesion was implicating the inferior portion of the left adrenal gland lateral limb, and exhibiting low to intermediate signal intensity on all provided sequences with signal dropout on out of the phase sequence. Moreover, minimal peripheral contrast enhancement was noted in the post-contrast administration images.

2.3 Diagnosis and Management

A few weeks later, the patient came back for his MRI reports. An expert review revealed that he was harboring a left adrenal adenoma,

consistent with the findings of the MRI where a focal, oblong lesion was noticed.

Sensing the seriousness of the situation, the patient was immediately sent to the surgery clinic for further evaluation and assessment. Here, the patient was given a 24-hour metanephrine test, which was negative.

Within the same week, the patient's tests and reports were repeatedly reviewed, and he was booked for a laparoscopic adrenalectomy the following week.

Following the laparoscopic adrenalectomy, the patient was kept under observation. Soon after the surgery, the patient was seen to have high blood pressure and low potassium levels, which raised concerns for an ensuing post-surgery complication.

Patient's blood pressure summary and comparison before and after surgery

BP reading before surgery			BP reading after recovery		
178 mmHg	188 mmHg	190 mmHg	138 mm Hg	119 mm Hg	126 mm Hg
	187 mmHg	188 mmHg	87 mm Hg	77 mm Hg	83 mm Hg

A summary of the patient's postoperative days is given below:

Day 1 Post Op:

- Kept under observation as per protocol.

Day 2 Post Op:

The patient was started on a medicine regime consisting of:

- Spironolactone (50 mg, BID)
- Valsartan (160 mg)
- Amlodipine (10 mg)

The patient's potassium levels were seen to improve from 3 mmol/lit to 3.3 mmol/lit.

2.4 Discharge Summary

On the 4th day post op, the patient was discharged in a stable state. Four days after

discharge, the patient was called in again for a follow-up appointment. He was examined and observed to have stable and controlled blood pressure. Since the blood pressure was within limits (not higher than 180/110 mm Hg), it was decided that his spironolactone and valsartan could be stopped.

On this day, the patient's potassium levels were also seen to be within the normal range. From this day onwards, the patient was advised to take only the Amlodipine (10 mg) once daily.

A month after this follow-up appointment, all antihypertensive medicines that the patient had been taking were stopped.

3. BIOPSY RESULTS

Narrated below are the biopsy result findings:

Table 3. Biopsy result findings

Specimen source: Left adrenal gland with tumor

The specimen was received in formalin labeled with the patient's name and medical record number. It consists of a single fibro fatty piece of tissue, measuring 7.5 x 5 x 3.0 cm including the adrenal gland. The specimen weighs 30.2 grams in total. The nodular fragment is attached to the rest of adrenal loosely, but can be easily separated from the tissue, measuring 1cm in maximum diameter and weighing 0.7 grams. The adrenal gland is partly cystic, measuring 5.5 x 2 x 1cm.

Pathology result

Adrenal gland tumor, resection:

- Features consistent with adrenal cortical adenoma.
- No necrosis or atypia is seen.
- Aldosterone secreting adenoma.

4. DISCUSSION

Adrenal adenomas are benign lesions that occur within the substance of the adrenal glands. These adenomas can either be functioning or non-functioning, depending on if they release any hormonal secretions. However, the majority of clinically diagnosed adrenal adenomas are found to be clinically silent. These adenomas might otherwise be over-secreting any hormone that they used to produce normally. In the context of the case presented here, the patient was suffering from an evident case of persistently elevated blood pressure levels. Now, primary aldosteronism is seen to be one of the leading causes of secondary hypertension in patients [6]. This patient was not suspected to suffer from primary hypertension because he had already been diagnosed with it a year earlier and had been started on an oral antihypertensive regimen, which did not help him at all. This failure was a clear indication that hypertension was occurring due to some other reason.

Once a patient has been documented to be suffering from primary aldosteronism, the next step is to obtain the patient's imaging studies. Imaging is important as it helps in diagnosing if the patient has any tumor or to prepare him for his subsequent surgery [7].

Coming back to the point, silent adrenal tumors are usually not problematic and are diagnosed as incidental findings. However, aldosterone-secreting tumors can arise in the form of symptomatic tumors that present as nothing but uncontrolled hypertension with seemingly no probable cause. However, uncontrolled blood pressure caused by this does not go down even when the patient is taking medication for it [8].

Once the patient has been confirmed as a case of unilateral primary aldosteronism, a laparoscopic adrenalectomy is now recommended. The choice of a laparoscopic approach over a traditional, open surgery is to avoid cardiovascular, renal, and other complications, to promote the control of the secretion of aldosterone and other hormones, and to reduce total recovery time post-surgery so that the patient can simultaneously be monitored and observed for any oncoming complications [9,10].

Once the laparoscopy was done, the patient was seen to have a stabilized condition, and there was no further risk of any hypertension or other complication present.

5. CONCLUSION

Secondary hypertension was seen as a rare cause of primary aldosteronism until recently. Now, the clinical diagnosis of uncontrolled hypertension is increasing yearly. When diagnostic tests reveal the adrenal glands are responsible, there is an immediate need to find the case of the myriad symptoms in the patient.

Thanks to the popular and advanced treatment therapy known as laparoscopy, adrenal tumors are now easily resected, and the patient can return to their normal condition as early as possible.

Laparoscopy reduces the post-surgery downtime and helps to keep the patient's condition in check after surgery, which is equally important.

CONSENT

As per international standard or university standard, patients' written consent has been collected and preserved by the author(s).

ETHICAL APPROVAL

As per international standard or university standard written ethical approval has been collected and preserved by the author(s).

COMPETING INTERESTS

Authors have declared that no competing interests exist.

REFERENCES

1. Megha R, Wehrle CJ, Kashyap S, et al. Anatomy, Abdomen and Pelvis, Adrenal Glands (*Suprarenal Glands*) [Updated 2021 Feb 10]. In: StatPearls [Internet]. Treasure Island (FL): StatPearls Publishing; 2021. Available: <https://www.ncbi.nlm.nih.gov/books/NBK482264/>
2. Dutt M, Wehrle CJ, Jialal I. Physiology, Adrenal Gland. [Updated 2021 May 9]. In: Stat Pearls [Internet]. Treasure Island (FL): Stat Pearls Publishing; 2021. Available :<https://www.ncbi.nlm.nih.gov/books/NBK537260/>
3. Byrd JB, Turcu AF, Auchus RJ. Primary Aldosteronism: Practical Approach to Diagnosis and Management. *Circulation*. 2018;138(8):823–835. Available :<https://doi.org/10.1161/CIRCULATIONAHA.118.033597>
4. Morimoto, R, Omata, K, Ito S, Satoh F. Progress in the management of primary aldosteronism. *American Journal of Hypertension*. 2018;31(5):522–531. Available:<https://doi.org/10.1093/ajh/hpy018>
5. Weiss LM. Comparative histologic study of 43 metastasizing and nonmetastasizing adrenocortical tumors. *Am J Surg Pathol*. 1984;8:163–169.
6. Paschou SA, Vryonidou A, Goulis DG. Adrenal incidentalomas: A guide to assessment, treatment and follow-up. *Maturitas*, 2016;92:79-85.
7. Rossi GP, Cesari M, Cuspidi C, Maiolino G, Cicala MV, Bisogni V, Mantero F, Pessina AC. Long-term control of arterial

- hypertension and regression of left ventricular hypertrophy with treatment of primary aldosteronism. *Hypertension*. 2013;62:62–69.
8. Indra T, Holaj R, Štrauch B, Rosa J, Petrák O, Šomlóová Z, Widimský J Jr. Long-term effects of adrenalectomy or spironolactone on blood pressure control and regression of left ventricle hypertrophy in patients with primary aldosteronism. *J Renin Angiotensin Aldosterone Syst*. 2015;16:1109–1117.
 9. Jones J, Niknejad M. Adrenal adenoma. Reference article, Radiopaedia.org; 2021.
Available: <https://doi.org/10.53347/rID-862>
 10. Update on CT and MRI of Adrenal Nodules by Schieda N, Siegelman ES. *AJR Am J Roentgenol*. 2017;208(6):1206-1217.

© 2021 Murad et al.; This is an Open Access article distributed under the terms of the Creative Commons Attribution License (<http://creativecommons.org/licenses/by/4.0>), which permits unrestricted use, distribution, and reproduction in any medium, provided the original work is properly cited.

Peer-review history:
The peer review history for this paper can be accessed here:
<https://www.sdiarticle5.com/review-history/77172>