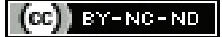

# Radiological Assessment of Pituitary Hyperplasia in Newly Diagnosed Cases of Primary Hypothyroidism after Hormone Therapy: A Longitudinal Study

MANOJ MATHUR<sup>1</sup>, RAJESH K BADHAN<sup>2</sup>, SUDESH KUMARI<sup>3</sup>, AMIT MEHTA<sup>4</sup>

## ABSTRACT

**Introduction:** With long-standing hypothyroidism, thyrotrophin hyperplasia can result in the enlargement of the pituitary gland. Regression of the hyperplasia has been shown to occur following adequate treatment of primary hypothyroidism with hormone replacement. Characteristics of pituitary gland hyperplasia on Magnetic Resonance Imaging (MRI) have been described previously in profound primary hyperthyroidism cases. But, hyperplasia and its regression have not been well-defined in newly diagnosed acute and uncomplicated cases after thyroid hormone therapy.

**Aim:** To assess pituitary gland size on MRI in the newly diagnosed acute cases of primary hypothyroidism after eight weeks of hormone replacement therapy.

**Materials and Methods:** This longitudinal study was carried out by enrolling 50 patients of recently diagnosed primary hypothyroidism in the Department of Radiodiagnosis, Government Medical College and Rajindra Hospital, Patiala, India from July 2018 to June 2021. In all newly diagnosed cases of primary

hypothyroidism, MRI of the pituitary gland was done and the size of the gland was measured in the coronal section before the start of treatment. MRI of all the patients was also done after treatment with levothyroxine at the interval of eight weeks to assess the size of pituitary gland. Student t-test was used for pre and post-treatment measurement. Data was entered in Microsoft (MS) excel and analysed using Statistical Package for Social Sciences (SPSS) software.

**Results:** Mean age of the patients included was 36.9±14.1 years. The mean Thyroid Stimulating Hormone (TSH), Triiodothyronine (T3), Triiodothyronine (T4) levels were 27.5±71.1 mIU/L, 0.72±0.33 ng/mL, and 3.6±1.4 mcg/dL, respectively. The mean size of the pituitary gland before treatment was 6.3±1.9 mm and after eight weeks of treatment was 5.5±1.9 mm (p=0.97).

**Conclusion:** This study does not find significant radiologically evident hyperplasia of pituitary gland in newly diagnosed cases of primary hypothyroidism, which might be because of MRI in the initial stage of the disease.

**Keywords:** Magnetic resonance imaging, Pituitary gland, Thyroid stimulating hormone

## INTRODUCTION

In hypothyroidism the thyroid gland is not producing enough of Triiodothyronine (T3), Tetraiodothyronine (T4) hormones leading to hypothyroidism [1]. Possible causes of hypothyroidism include severe iodine deficiency, post-thyroidectomy, radiation therapy, Hashimoto's thyroiditis, and central hypothyroidism [2]. Hypothyroidism is detected by checking serum T3, T4, and Thyroid-Stimulating Hormone (TSH) levels. If TSH is over 5 mU/L (milliunits per litre) then it is considered to be high. Levothyroxine (L-thyroxine) is used to replace thyroxine when T4 levels are low [3]. With long-standing and profound hypothyroidism, there is enlargement of the pituitary gland due to hyperplasia of TSH producing thyrotrophin with hormone replacement in cases of hypothyroidism, this hyperplasia is reversed leading to a decrease in pituitary size [4]. First such case was reported in 1851 by Niepce [5]. Pituitary enlargement with primary hypothyroidism has been seen in up to 81% of patients [6]. In 1978, Jawadi MH et al., reported the reduction of pituitary size following thyroxine therapy [7].

Computed Tomography (CT) scan or MRI scans are fairly accurate method to assess pituitary gland size [8,9]. Most of the literature has described reduction in pituitary size to occur only after four weeks of the initiation of thyroid hormone therapy [8,10-12]. All other studies published in literature usually include long-standing hypothyroidism cases, but in present study, newly diagnosed cases of primary hypothyroidism were included which were diagnosed on routine screening without long-standing history or symptoms [10-12].

The aim of the study was to assess pituitary gland size on MRI in the newly diagnosed acute cases of primary hypothyroidism after eight weeks of hormone replacement therapy.

## MATERIALS AND METHODS

This was a longitudinal study carried out in the Department of Radiodiagnosis, Government Medical College, and Rajindra Hospital, Patiala, India, from July 2018 to June 2021. Internal Ethics Committee approval was taken before starting the study with letter number BFUHS/2K18p-111/5255, dated 29/05/2018. Informed consent of the subjects was obtained.

Fifty patients who were referred to Radiodiagnosis Department after a recent diagnosis of primary hypothyroidism were included in this study.

### Inclusion criteria:

- Newly diagnosed cases of primary hypothyroidism.
- Patient giving consent for MRI and who were willing to enroll in study.

### Exclusion criteria:

- Patient having cardiac pacemaker, electromagnetic implant.
- Patient with central hypothyroidism.

### Study Procedure

Plain MRI and Dynamic Contrast Enhanced- MRI (DCE-MRI) were done in all patients using a 1.5T superconductive scanner (Siemens

1.5T Magnetom Aera MRI machine). MRI protocol includes sagittal and coronal T1-weighted plus coronal T2-weighted spin-echo sequences performed using a reduced field of view focused on the sellar region.

After fulfilment of all the inclusion and exclusion criteria, plain MRI and DCE-MRI of pituitary were done. Detection and quantification of pituitary gland size was done by measuring height of pituitary gland in the coronal section [13]. Patients were treated with levothyroxine with starting dose of 1.7 mcg/kg/day. All patients were rescanned after an interval of eight weeks to reassess the size of the pituitary gland after hormone replacement therapy. Post-treatment MRI was done free of cost under academic/research heading.

## STATISTICAL ANALYSIS

Data was entered in MS excel and analysed using SPSS software. Data was expressed in percentage as appropriate statistical analysis was performed. Normality of the measurable data was tested by, Kolmogorov-Smirnov test. Groups were compared for normally distributed data by student t-test for pair-wise comparison. The level of significance was taken at 5% level.

## RESULTS

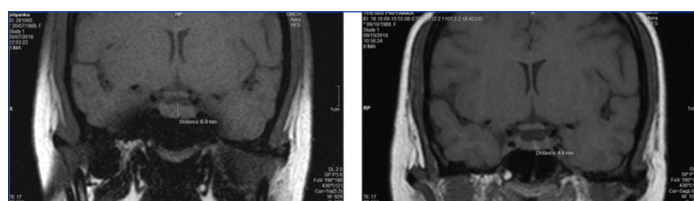
Mean age of the patients in this study was 36.9±14.1 years. Forty three (86%) patients were female and 7 (14%) patients were males. The most common chief complaint was weight gain in 15 (30%) patients. Other chief complaints were myalgia in 12 (24%) patients, weakness in 9 (18%) patients, menorrhagia in 9 (18%) patients, headache in 4 (8%) patients and infertility in 1 (2%) patient. None of the patient had any visual complaint, any neurological symptom or history suggestive of galactorrhoea. Brief results analysis as a whole is given in [Table/Fig-1].

Variables	Age	TSH level (ng/dL)	T3 level (ng/dL)	T4 level (ng/dL)	Pituitary size (mm) before RX	Pituitary size (mm) after 8 weeks of RX
Mean±SD	36.9±14.1	27.5±71.1	0.72±0.33	3.59±1.4	6.33±1.91	5.5±1.9
Minimum	14	5.3	0.1	0.8	1.3	1.3
Maximum	75	500	1.2	6.2	10.4	10.4

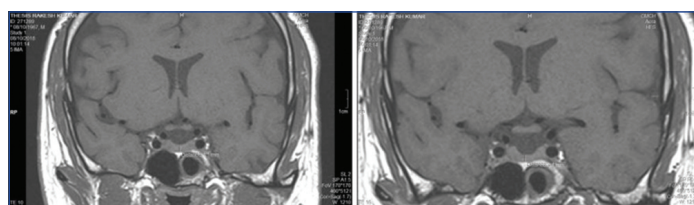
[Table/Fig-1]: Brief result analysis.

p-value: 0.97 ( Non significant)

The MRI scan was done to assess the size of the pituitary gland in all the enrolled patients after eight weeks of hormone replacement therapy. Thirty (60%) patients were found to have reduction in their pituitary sizes in subsequent MRI scans. Nineteen (38%) patients didn't show any reduction in their pituitary sizes in subsequent MRI scan. One patient had empty sella on both the MRI scans. [Table/Fig-2a,b] of MRI images show size of the pituitary gland in a patient before and after hormone replacement therapy, respectively. Similarly [Table/Fig-3a,b] show pre and post-treatment size of pituitary gland of another patient.



[Table/Fig-2]: a) Coronal MRI T1W image of patient-1 show pituitary gland size before treatment, b) After hormone replacement therapy.



[Table/Fig-3]: a) Coronal MRI T1W image of patient showing pituitary gland size before treatment, b) After hormone replacement therapy.

## DISCUSSION

The mean thyroid stimulating hormone level of the patients included in present study was 27.5±71.1 µIU/mL, ranging from 5.3-500 µIU/mL. In a study conducted by Nahla M et al., 31 of the 37 patients (84%) had TSH levels of more than 100 µIU/mL [14]. In a study conducted by Han L et al., the plasma T3 and T4 of all the patients were below the normal levels and plasma TSH levels in these patients were between 85 and 190 µIU/mL [15]. In a study conducted by Kamble RB et al., T3 levels ranged from 0.34-0.51 ng/mL, T4 ranged from less than 1-1.34 mcg/dL, TSH more than 75 µIU/mL in all patients [16]. All the published studies as described had patients with high TSH levels more than 75 µIU/mL, while in present study the mean TSH level of the patients included was 27.5±71.1 µIU/mL.

The size of the pituitary gland of the patients in present study before treatment was 6.3±1.9 mm ranging from 1.3-10.4. Second MRI scan was done in all the patients eight week after the treatment. The size of pituitary gland of the included patients in present study after eight weeks of treatment was 5.5±1.9, ranging from 1.3-10.4. In a study conducted by Nahla M et al., 85% of the patients with pituitary enlargement who underwent a follow-up MRI showed a decrease in size of the gland [14]. Han L et al., demonstrated the diameters of pituitary gland were between 1.1 to 2.5 cm. All patients had reduction in pituitary size post-treatment [15]. Kamble RB et al., reported the height of pituitary gland on coronal section at presentation was 15.73±3.31 mm and after treatment was 13.04±3.46 mm all the patients had reduced size on subsequent MRI scans [16]. Pituitary size before treatment across various published studies ranged from 13.2 to 15.7 mm and reduction in the pituitary size following hormone replacement ranged from 85% to 100% [14-16].

Present study does not find significant pituitary hyperplasia and increase in size of the pituitary gland on first MRI in patients with newly diagnosed primary hypothyroidism cases. This finding might be because of early presentation and early enrollment of patients in this study. Pituitary hyperplasia is both time-bound and also related to extent of hypothyroidism. So, profound hypothyroidism might be the reason for the high incidence of pituitary hyperplasia in published literature. Another possible reason that could explain time bound hyperplasia and increase pituitary size in published literature may be delayed presentation of the patients to their health services.

## Limitation(s)

Patient included in present study was diagnosed clinically in early stage of disease so there was not significant derangement of thyroid hormonal level or hyperplasia of pituitary gland.

## CONCLUSION(S)

In primary hypothyroidism, MRI can be used to know the pituitary gland size before start of treatment and to assess response after some interval of hormone replacement therapy. However, radiologically evident increase in the size of the pituitary gland require profound and possibly long standing hypothyroidism, which regresses to its original size after oral hormone replacement therapy.

## REFERENCES

- [1] Bianco AC, Salvatore D, Gereben B, Berry MJ, Larsen PR. Biochemistry, cellular and molecular biology, and physiological roles of the iodothyronine selenodeiodinases. *Endocr Rev.* 2002;23(1):38-89.

- [2] Takamatsu J, Yoshida S, Yokozawa T, Hirai K, Kuma K, Ohsawa N, et al. Correlation of antithyroglobulin and antithyroid-peroxidase antibody profiles with clinical and ultrasound characteristics of chronic thyroiditis. *Thyroid*. 1998;8;12:1101-06.
- [3] Vanderpump MP, Ahlquist JA, Franklyn JA, Clayton RN. Consensus statement for good practice and audit measures in the management of hypothyroidism and hyperthyroidism. The Research Unit of the Royal College of Physicians of London, the Endocrinology and Diabetes Committee of the Royal College of Physicians of London, and the Society for Endocrinology. *BMJ*. 1996;313(7056):539-44.
- [4] Sarlis N, Brucker-Davis F, Doppman J, Skarulis M. MRI demonstrable regression of a pituitary mass in a case of primary hypothyroidism after a week of acute thyroid hormone therapy. *J Clin Endocrinol Metabol*. 1997;82:808-11.
- [5] Fujii T, Misumi S, Onoda K, Fukuda H, Ibuki Y. Pituitary enlargement with target organ deficiency: Hypothyroidism and hypogonadisms. *Surg Neurol*. 1987;28:390-94.
- [6] Yamada T, Tsukui T, Ikejiri K, Yukimura Y, Kotani M. Volume of sellaturcica innormal subjects and in patients with primary hypothyroidism and hyperthyroidism. *J Clin Endocrinol Metab*. 1976;42:817-22.
- [7] Jawadi MH, Ballonoff LB, Stears JC, Katz FH. Primary hypothyroidism and pituitary enlargement. Radiological evidence of pituitary regression. *Arch Intern Med*. 1978;138:1555-57.
- [8] Yamamoto, Saito K, Takai T, Naito M, Yoshida. Visual field defects and pituitary enlargement in primary hypothyroidism. *J Clin Endocrinol Metabol*. 1983;57:283-87.
- [9] Pita JC Jr, Shafey S, Pina R. Diminution of large pituitary tumor after replacement therapy for primary hypothyroidism. *Neurology*. 1979;29(8):1169-72.
- [10] Wolanski LJ, Leavitt GD, Elias BJ, Lee HJ, Dasmahapatra A, Byrne W. MRI of pituitary hyperplasia in hypothyroidism. *Neuroradiology*. 1996;38:50-52.
- [11] Silver BJ, Kyner JL, Dick AR, Chang CHJ. Primary hypothyroidism: Suprasellar pituitary enlargement and regression on computed tomographic scanning. *JAMA*. 1981;246:364-65.
- [12] Hutchins WW, Crues JV, Miya P, Pojunas KW. MR demonstration of pituitary hyperplasia and regression after therapy for hypothyroidism. *Am J Neuroradiol*. 1990;11:410.
- [13] Sarlis NJ, Brucker-Davis F, Doppman JL, Skarulis MC. MRI-demonstrable regression of a pituitary mass in a case of primary hypothyroidism after a week of acute thyroid hormone therapy. *J Clin Endocrinol Metab*. 1997;82(3):808-11.
- [14] Khawaja NM, Taher BM, Barham ME, Naser AA, Hadidy AM, Ahmad AT, et al. Pituitary enlargement in patients with primary hypothyroidism. *Endocrine Practice*. 2006;12(1):29-34.
- [15] Han L, Wang J, Shu K, Lei T. Pituitary tumorous hyperplasia due to primary hypothyroidism. *Acta Neurochir (Wien)*. 2012;154(8):1489-92.
- [16] Kamble RB, Babu S, Nagaraj D, Mudakavi SJ. Time bound regression of pituitary hyperplasia in primary pituitary hypothyroidism following treatment. *West Afr J Radiol*. 2016;23:20-22.

#### PARTICULARS OF CONTRIBUTORS:

1. Professor, Department of Radiodiagnosis, Government Medical College and Rajindra Hospital, Patiala, Punjab, India.
2. Assistant Professor, Department of Radiodiagnosis, Government Medical College and Rajindra Hospital, Patiala, Punjab, India.
3. Assistant Professor, Department of Pulmonary Medicine, Government Medical College, Patiala, Punjab, India.
4. Junior Resident, Department of Radiodiagnosis, Government Medical College and Rajindra Hospital, Patiala, Punjab, India.

#### NAME, ADDRESS, E-MAIL ID OF THE CORRESPONDING AUTHOR:

Rajesh K Badhan,  
H. No. B-56, PDA OMAXE City, Patiala, Punjab, India.  
E-mail: drbadhan@gmail.com

#### PLAGIARISM CHECKING METHODS: [Jain H et al.]

- Plagiarism X-checker: Nov 19, 2022
- Manual Googling: Jan 10, 2023
- iThenticate Software: Feb 02, 2023 (11%)

#### ETYMOLOGY: Author Origin

#### AUTHOR DECLARATION:

- Financial or Other Competing Interests: None
- Was Ethics Committee Approval obtained for this study? Yes
- Was informed consent obtained from the subjects involved in the study? Yes
- For any images presented appropriate consent has been obtained from the subjects. Yes

Date of Submission: **Nov 09, 2022**

Date of Peer Review: **Dec 07, 2022**

Date of Acceptance: **Feb 04, 2023**

Date of Publishing: **Mar 01, 2023**