

## **Aesthetic Considerations When Restoring Single Maxillary Central Incisor**

**Ahmed Besrou<sup>1\*</sup>, Nissaf Daouahi<sup>1</sup>, Dalenda Hadyaoui<sup>1</sup>, Adel Amor<sup>2</sup>  
and Mounir Cherif<sup>1</sup>**

<sup>1</sup>Department of Fixed Prosthodontics –Dentistry School, Tunisia.

<sup>2</sup>Department of Dental Medicine, Sahloul Hospital –Dentistry School, Tunisia.

### **Authors' contributions**

*This work was carried out in collaboration between all authors. Author AB worked with author ND on structuring, writing the manuscript and collecting also the references part. Authors AB and AA took the photos and carried out the clinical procedure. Author DH guided structuring and writing the manuscript and provided the necessary corrections. Author MC supervised and provided the necessary materials.*

### **Article Information**

DOI: 10.9734/AJDS/2018/45136

#### Editor(s):

(1) Dr. Mehmet Yaltirik, Department of Oral Surgery and Medicine, Faculty of Dentistry, Istanbul University, Istanbul, Turkey.

#### Reviewers:

(1) J. Muruganandhan, Sri Venkateswara Dental College and Hospital, India.

(2) Alper Özdoğan, Atatürk University, Turkey.

(3) Mona Ionas, Lucian Blaga University of Sibiu, Romania.

Complete Peer review History: <http://www.sciencedomain.org/review-history/27872>

**Case Study**

**Received 17 September 2018**

**Accepted 05 December 2018**

**Published 19 December 2018**

### **ABSTRACT**

The aim of this article is to illustrate the aesthetic rehabilitation of a discoloured maxillary central incisor according to dominance principle based on establishing ideal proportions.

The factors that can affect the aesthetic value of a dental supported crown in the aesthetic zone are also discussed.

These parameters include abutment colour, ceramic thickness, the opacity of luting agent and gingival contours.

The article describes a clinical situation of restoring a discoloured maxillary central incisor using an all ceramic crown. The patient presented with a hidden smile and was asking for improvement of its aesthetic appearance. Clinical examination showed a discrepancy between the central incisors.

The treatment plan included crown lengthening followed by Lithium Disilicate Ceramic crown. The opacity of the material was selected according to the abutment discoloration.

An IPS Natural Die Material shade guide was also used. The restoration was bonded using a resin material. Finally, Pink/white aesthetic score PES/WES was applied to evaluate the aesthetic outcome.

**Keywords:** Maxillary central incisor; aesthetics; glass ceramics; luting agent; abutment teeth colour.

## 1. INTRODUCTION

Restoring maxillary central incisor is a challenging task for prosthodontists. In fact, the morphological features are closely correlated with facial proportions and they present influential factors in the aesthetic perception. Williams et al. [1] demonstrated that the tooth shape is determined by facial form. Whereas, many other studies have found no correlation between facial outline and preferred tooth shape [2]. The central incisor should be the most dominant tooth displayed during the smile. Several tools have been suggested for assessing its dominance such as shape, size, shade, incisal edge position and proportions. They constitute starting points for aesthetic management of maxillary central incisor [3,4]. In fact, the width of a maxillary central incisor is expected to be proportional to its length which determines the width/Length ratio. According to literature, it was evaluated to be between 75% and 78% [5]. Recent studies demonstrated similarities between professionals and non-professionals regarding the dominance of central incisor in dental aesthetic perception [6]. They, both, don't accept any reduction in an average central incisor length. However, a reduction of the width of lateral incisor about 0.5 mm can be unperceived [5]. According to Spear & Kokich [7], establishing correct proportions of a central incisor depends also on achieving ideal gingival levels especially when gingival contours are altered.

In the same context, assessing the papilla level relatively to the overall crown length of maxillary central incisor is also considered as an important criterion. It is in fact an important step in the process of establishing a correct position of maxillary anterior teeth. Dark abutments may negatively affect the aesthetic value of a translucent ceramic crown conducting to a discolouration of the restoration in the cervical area. Therefore, material selection depends on the degree of abutment colour. With translucent ceramics, the final aesthetic result is, according to recent studies, interplaying between multiple parameters including ceramic thickness, substrate shade and luting agent colour [8]. For

correct restoration colour match, clinician needs to have basic knowledge of light science. He is, also, considered to be responsible for creating a less confusing communication with the laboratory via some tools such as graphics, shade mapping cards, aesthetic checklists and a shade guide.

Using reliable indices for objective aesthetic evaluation is a fundamental step in order to monitor the results over time. Various indices such as pink/white aesthetic score (PES/WES) were proposed. According to the literature [9], this score is recommended to both soft and hard tissues evaluation in implant supported restorations. PES was introduced by Fürhauser et al. [9].

The PES index involved the following five variables: Mesial papilla, distal papilla, the level and curvature of the facial mucosa, root convexity, and soft-tissue colour and texture at the facial side of the implant. For mesial and distal papilla, a score of 2 (Complete), 1 (Incomplete), and 0 (Absent) were assigned.

For the remaining three PES parameters, a score of 2 (no discrepancy), 1 (minor discrepancy), and 0 (major discrepancy) were assigned. The highest possible score would be 10 and the threshold of clinical acceptability was set at 6 [10]. WES was based on the five following parameters: general tooth form, outline and volume of the clinical crown, color including the assessment of hue and value, surface texture, translucency, and characterisation. A score of 2 was given if there was no discrepancy; score 1 for minor discrepancies; and score 0 for any major discrepancy observed. A maximum total WES was 10 and the threshold of clinical acceptance was set at a score of 6 [10]. It's validity for natural tooth was discussed recently by authors [11].

## 2. CASE REPORT

This clinical presentation is dealing with the rehabilitation of a discoloured a central incisor. It concerns a 23-year-old female patient with a chief complaint of poor aesthetics. She was bothered by the discrepancy between the maxillary central incisors. Intra oral examination

revealed a resin composite restoration on the affected tooth with discoloured margins. The patient presents a convex profile with parallel commissural and mid-pupillary lines. No harmonious smile lines with squared teeth form and size discrepancies were noticed. Photographs were taken using Nikon D7100 a Camera (Nikon, Tokyo, Japan). Periodontal probing revealed a thick gingival biotype, with gingival thickness of 02 mm and a sulcus depth of 02 mm. Altered gingival contours, leading to inadequate Width-to-height ratio and discrepancy between the two central incisors, were also detected (Fig. 1). Radiological examination showed an adequate canal root treatment (Fig. 2). The treatment procedure started by a periodontal treatment consisting on periodontal scaling, followed then by aesthetic crown lengthening and Lithium Disilicate Ceramic crown. Shade selection was performed before any procedure to avoid dehydration of the tooth. A colour mapping card was performed referring to the right central incisor. The tooth was prepared for all ceramic crown with internal rounded shoulder at sub gingival level edges with no sharp angles (Fig. 3). The abutment tooth shade was, then, determined using the IPS Natural Die Material shade guide (Ivoclar Vivadent, Schaan, Liechtenstein).

Firstly, a handmade provisional restoration, with precisely fitting and highly polished margins was performed using resin material Texton (SS White, New Jersey, USA). Crown lengthening was performed. Then, a second indirect provisional restoration was manufactured by CAD-CAM technique (CEREC system) using PMMA (methymethacrylate based resin) with higher mechanical properties. It gives the technician sufficient time to fabricate the ceramic crown. Final restoration was, then, performed using Lithium Disilicate Ceramic material IPS e.max CAD (Ivoclar Vivadent, Schaan, Liechtenstein); high translucency block was used (HT A1/ I12). An aesthetic try in of the crown before crown staining and glazing allows verification of the crown morphology and color. At this stage, the incisal edge position, the midline, the axial inclination, the gingival margins and the papilla level should be verified (Fig. 4).

The crown was bonded using dual cured resin luting cement Variolink N (Ivoclar Vivadent, Schaan, Liechtenstein) according to the protocol described by Magne and Cascione [12].

First, the internal surface of the crown was thoroughly rinsed with water then cleaned with

alcohol. Second, the ceramic restoration was etched during 60 to 90 sec using HFI 9% acid (Ivoclar Vivadent, Schaan, Liechtenstein). Then fresh silane was applied for 60 seconds. On the other side, the tooth surface was etched with 36% orthophosphoric acid.

Finally, bonding agent was applied. All cement should be removed before, and any remaining residue should be removed with a sickle scaler or a #12 scalpel blade. The final restoration was assessed using White/ Pink esthetic score (WES/PES). Significant differences between the initial and final scores of the WES/PES were evident. The white score (WES) was increased from (1/10) to (8/10); however, the Pink score (PES) was improved from (5 /10) to (9/10) (Fig. 5). This improvement is noticed on gingival health showing no more inflammation and better architecture compared to the initial situation. When it comes to white assessment, the final situation shows a natural mimicry in terms of shape, color, and texture and incisal edge position.

### 3. DISCUSSION

Restoring single central incisor, according to the principle of dominance, remains a challenge for prosthodontists. In fact, central incisor can have three main shapes square, tapered or triangular [1].

According to a recent systematic review, which was dealing with lay preferences for dentogingival aesthetic parameters; it has been shown that tapered incisors are the most attractive in both male and female [13].

The incisal edge position of the central incisor is of great importance in aesthetic perception; it should be parallel to mid-pupillary line. As mentioned by authors, vertical asymmetries as small as 0.6 mm were perceived as unacceptable according to Brazilian population [14].

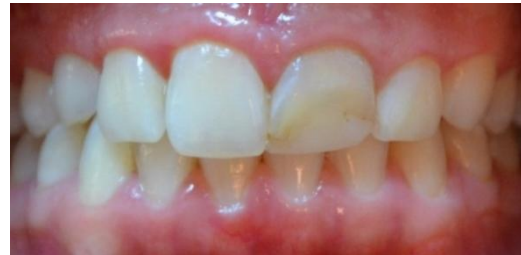Aesthetic crown lengthening contributes not only to getting the correct width –To Length ratio, but also to the correction of gingival asymmetries [5].

The management of the provisional restoration after aesthetic crown lengthening is a fundamental step. Its role is essential for the healing process. It, also, allows the verification of the shape of the tooth. Precisely fitting and highly polished margins are strongly

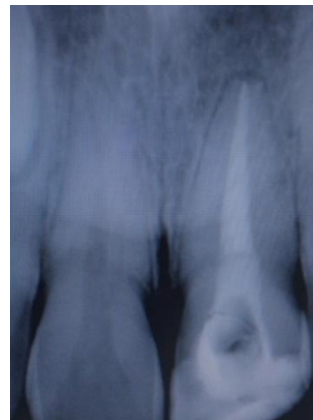recommended [15]. They should be placed prior to crown lengthening and then modified according to new gingival levels [16].

As mentioned by authors, soft tissue healing is mostly completed after 8 weeks. Definitive restoration can be, then, successfully placed within 8–12 weeks. The impression step should be delayed until a subsequent appointment once soft tissue health has been re-established [15]. Ceramic material selection is depending on the abutment shade. High translucent materials are generally rejected in favor of opacous ones in case of discolored underlying substrate [16]. As recommended by authors, a ceramic thickness of 0.2 mm is sufficient to mitigate the dark aspect of the underlying substrate [17]. Characterisation of central incisor surface texture is as important as matching the shade. Indeed, it is important to consider anatomical shape characterising the buccal surface of the central. Three ridges and two concavities were overall created to mimic a natural micro-geography aspect. Resin cement may cause visually non-aesthetic colour changes with thin ceramic restorations; the colour change effect decreases when the ceramic thickness increases. It concerns especially laminate veneers of 0.5 to 1 mm of thickness [17]. According to literature, WES /PES index was essentially recommended to evaluate supported implant restorations, but its rightness for

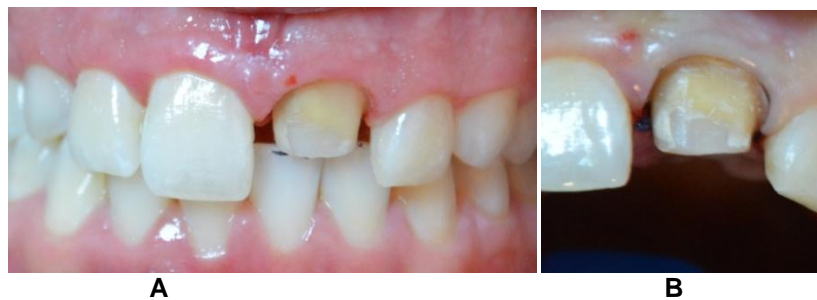objective evaluation of single tooth crown has been confirmed by recent studies [11].



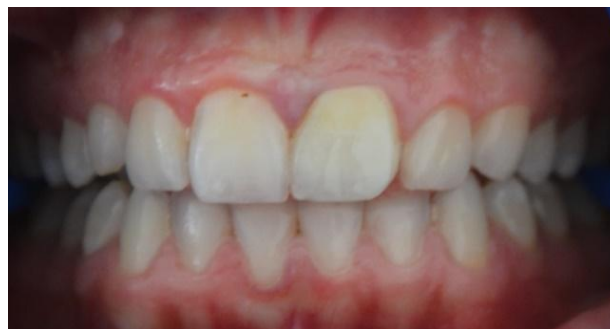**Fig. 1. Retracted preoperative full-mouth view showing discolored margins of resin**



**Fig. 2. Radiological examination**



**Fig. 3. Abutment tooth after healing period: Tooth preparation**



**Fig. 4. Retracted close-up postoperative view of the maxillary anterior restoration**

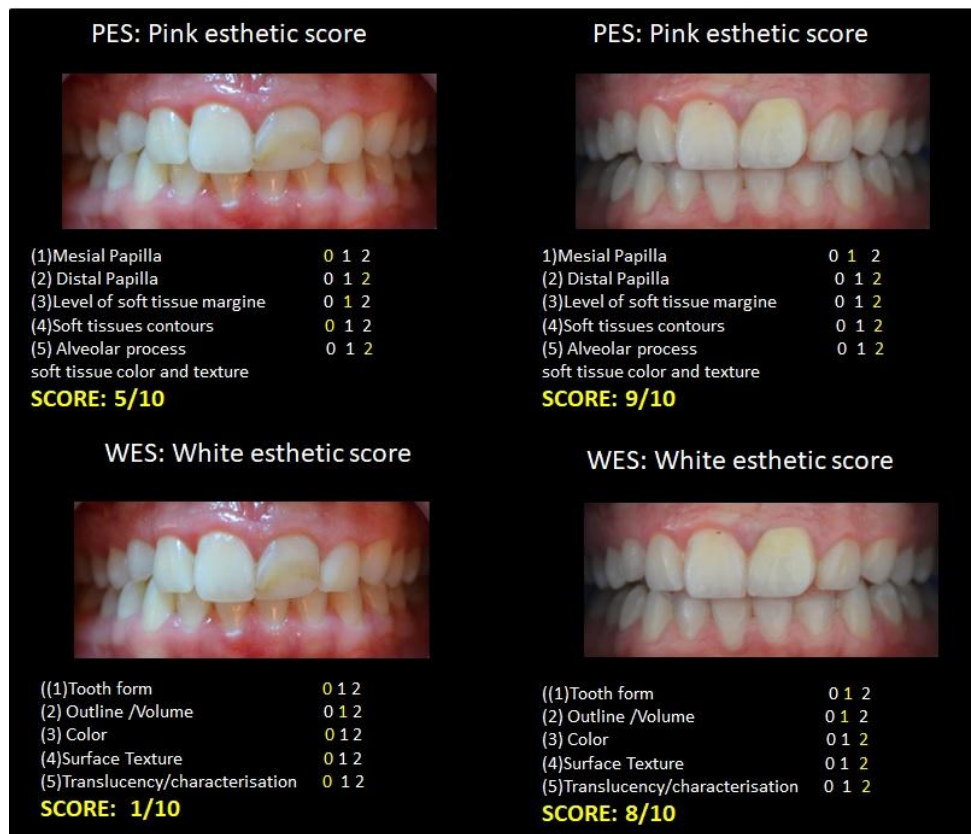


Fig. 5. Initial WES/PES versus final WES/PES

#### 4. CONCLUSIONS

Restoring single central incisor, according to the principle of dominance, remains a challenge for prosthodontists; for that some guidelines regarding the shade, proportions, size should be respected.

The underlying tooth structure has a primary effect on the appearance of the definitive ceramic restoration. To eliminate this undesirable effect, factors such as ceramic thickness, ceramic shade and cement colour should be considered. Shade selection, ceramic material selection and appropriate communication with the laboratory technician are combined factors for success.

#### CONSENT

As per international standard or university standard, patient's written consent has been collected and preserved by the authors.

#### ETHICAL APPROVAL

All the information of participants was kept anonymously and secretly and all the ethical principles were considered.

#### ACKNOWLEDGEMENTS

The authors would like to thank colleagues from the department of prosthodontics for their support. A special thank for the laboratory technician who performed the restorations.

#### COMPETING INTERESTS

Authors have declared that no competing interests exist.

#### REFERENCES

- Williams JL. A new classification of human tooth forms with reference to a new system of artificial teeth. Dent Cosmos. 1914;56:627-628.
- Anderson KM, Behrents RG, McKinney T, Buschang PH. Tooth shape preferences in an esthetic smile. Am J Orthod Dentofacial Orthop. 2005;128:458-65.
- Hasanreisoglu U, Berksun S, Aras K, Arslan I. An analysis of maxillary anterior teeth: Facial and dental proportions. J Prosthet Dent. 2005;94:530-8.
- Petropoulou A, Pappa E, Pelekanos S. Esthetic considerations when replacing

- missing maxillary incisors with implants: A clinical report. *J Prosthet Dent.* 2013;109:140-144.
5. Snow SR. Esthetic smile analysis of anterior tooth width: The golden percentage. *J Esthet Dent.* 1999;11:177-84.
  6. Shetty S, Pitti V, Satish Babu C, Surendra Kumar G, Jnanadev K. To evaluate the validity of recurring esthetic dental proportion in natural dentition. *J Conserv Dent.* 2011;14:314-7.
  7. Spear FM, Kokich VG. A multidisciplinary approach to esthetic dentistry. *Dent Clin N Am* 51. 2007;487-505.
  8. Chaiyabutr Y, Kois JC, LeBeau D, Nunokawa G. Effect of abutment tooth color, cement color, and ceramic thickness on the resulting optical color of a CAD/CAM glass-ceramic lithium disilicate reinforced crown. *J Prosthet Dent.* 2011;105:83-90.
  9. Fürhauser R, Florescu D, Benesch T, Haas R, Mailath G, Watzek G. Evaluation of soft tissue around single-tooth implant crowns: The pink esthetic score. *Clin Oral Implants Res.* 2005;16:639-644.
  10. Lavigne SE, Krust-Bray KS, Williams KB, Killooy WJ, Theisen F. Effects of subgingival irrigation with chlorhexidine on the periodontal status of patients with HA-coated integral dental implants. *Int J Oral Maxillofac Implants.* 1994;9:156-162.
  11. Lanza A, Di Francesco F, De Marco G, Femiano F, Itró A. Clinical application of the PES/WES index on natural teeth: Case report and literature review. *Case Rep Dent;* 2017.
  12. Magne P, Cascione D. Influence of post-etching cleaning and connecting porcelain on the microtensile bond strength of composite resin to feldspathic porcelain. *The Journal of Prosthetic Dentistry.* 2006;96(5):354-361.
  13. Del Monte S, Afrashtehfar KI, Emami E, Abi Nader S, Tamimi F. Lay preferences for dentogingival esthetic parameters: A systematic review. *J Prosthetic Dent.* 2017;118(6):717-724.
  14. Machado AW, Moon W, Gandini LG. Influence of maxillary incisor edge asymmetries on the perception of smile esthetics among orthodontists and laypersons. *American Journal of Orthodontics and Dentofacial Orthopedics.* 2013;143(5):658-664.
  15. Fletcher P. Biological rationale of aesthetic crown lengthening using innovative proportion gauges. *International J. Periodontics Restorative Dent.* 2011;31:523-532.
  16. Calandriello M, Carnevale G, Ricci G. *Parodontologia.* Bologna: Martina Press; 1980.
  17. Sedanur Turgut, Bora Bagis. Effect of resin cement and ceramic thickness on final color and laminate veneers: An *in vitro* study. *Journal of Prosthetic Dentistry.* 2013;109:179-186.

© 2018 Besrouer et al.; This is an Open Access article distributed under the terms of the Creative Commons Attribution License (<http://creativecommons.org/licenses/by/4.0>), which permits unrestricted use, distribution, and reproduction in any medium, provided the original work is properly cited.

*Peer-review history:*

The peer review history for this paper can be accessed here:  
<http://www.sciencedomain.org/review-history/27872>