



An Extremely Rare Case of Small Bowel Strangulation Due to Meckel's Diverticulum

Sopan N. Jatal ^{a*}, Sudhir Jatal ^{b++} and Sachin Ingle ^{c#}

^a Jatal Hospital and Research Centre, Latur, India.

^b Jatal Hospital and Research Centre, Latur, Tata Hospital, Mumbai, India.

^c Department of Pathology, MIMSR Medical College, Latur, India.

Authors' contributions

This work was carried out in collaboration among all authors. All authors read and approved the final manuscript.

Article Information

Open Peer Review History:

This journal follows the Advanced Open Peer Review policy. Identity of the Reviewers, Editor(s) and additional Reviewers, peer review comments, different versions of the manuscript, comments of the editors, etc are available here: <https://www.sdiarticle5.com/review-history/101854>

Case Study

Received: 14/04/2023

Accepted: 16/06/2023

Published: 24/06/2023

ABSTRACT

Meckel's diverticulum is the most common congenital gastrointestinal anomaly. Intestinal obstruction is the common presenting symptom in the adult population, due to complications like intussusception, Incarceration, adhesion and torsion around a fibrous band attached to the umbilicus. The life time risk of complication is 4-9%. It is an uncommon cause of acute intestinal obstruction in adults. Strangulation of small bowel with an encircling Meckel's diverticulum around the base of the mesentery or loop formation of Meckel's diverticulum leading to small bowel obstruction is an extremely rare event causing strangulation of small bowel and high mortality if the treatment is delayed.

We present a case report of a 15 years-old boy, who present with small bowel obstruction, requiring an emergency laparotomy. He was found a strangulated loop of small bowel with an encircling Meckel's diverticulum around the base of the mesentery. So five feet of gangrenous small bowel along with Meckel's diverticulum is resected and end to end anastomosis done.

⁺⁺ Fellow in Colorectal Cancer;

[#] Professor;

*Corresponding author: E-mail: jatalhospital@gmail.com;

Keywords: Small bowel obstruction; Meckel's diverticulum; explorative laparotomy.

1. INTRODUCTION

"Meckel's diverticulum is the most common congenital anomaly of the gastrointestinal tract and has been reported in 2% of population, 2 feet away from the ileocecal junction and 2 inches in length. It is common in males than in females with a ratio of 2:1" [1]. Most Meckel's diverticulum cases are asymptomatic which are diagnosed incidentally during diagnostic imaging or at the time of surgical exploration.

"Obstruction of the small intestine, lower Gastrointestinal bleeding and inflammation of Meckel's diverticulum are some presenting complications in the symptomatic patient. 21.8% of all acute surgical emergency are related to intestinal obstruction" [1,2,3].

"Meckel's diverticulum causing intestinal obstruction is due to inverted Meckel's diverticulum, intussusception or a volvulus around an attached fibrous band to the umbilicus, Mesodiverticular band with small bowel obstruction, Littre's hernia and axial torsion of Meckel's diverticulum is considered a rare complication" [1,4,5].

2. CASE REPORT

A 15 years -old boy was admitted at our centre on 23/05/2010, with complaints of Severe abdominal pain, distention of abdomen, vomiting and constipation last 2 days. On clinical examination there was abdominal distension along with tenderness all over the abdomen. His vital signs were within normal limits but signs of dehydration were present. Total leukocyte count was 17,500 cmm. Renal function tests were normal. Abdominal Plain x-ray revealed multiple air-fluid levels which suggestive of small bowel obstruction.

Explorative laparotomy was planned. Intraoperative Meckel's diverticulum was found attached to mesentery by its distal end, thus forming a loop. To our surprise we found a pedunculated Meckel's diverticulum having a stalk of 3 cm in length causing looping around the small bowel, leading to strangulation and gangrene. A five feet segment of the ileum was gangrenous, En-bloc resection of the

gangrenous segment of bowel along with Meckel's diverticulum was performed and end to end anastomosis done in two layers. The patient had uneventful postoperative recovery and discharged home on 8th postoperative day. The histopathological report of resected specimen was Meckel's diverticulum without any ectopic tissue (Figs. 1, 2, 3, 4).

3. DISCUSSION

Meckel's diverticulum is the most common congenital anomaly of gastrointestinal tract. First recognized by Johann Fedrich Meckel and its developmental origin in 1809. "It is a true diverticulum composed of all three layers of intestine. Meckel's diverticulum is located on the antimesenteric border of the ileum, its typically found within 30 cm to 100 cm proximal to ileocecal junction" [3].

"Only about 4-9% of the Meckel's diverticulum patient becomes symptomatic, while other remains asymptomatic for life. Small bowel obstruction, lower gastrointestinal bleeding and diverticulitis are the most common presentations of symptomatic Meckel's diverticulum" [3]. Salzer discovered "the ectopic gastric mucosa in Meckel's diverticulum and lower gastrointestinal bleeding is usually encountered secondary to the ectopic gastric mucosa and diverticulitis commonly occurs due to acid secretion from the ectopic gastric mucosa" [3].

"Abdominal pain, abdominal distension, constipation and vomiting are the salient features of acute intestinal obstruction. Multiple air-fluid levels in diagnostic imaging in x-ray abdomen and CT abdomen of small bowel obstruction" [3,6,7].

In our case we found strangulated loop of small bowel with gangrene, due to encircling of Meckel's diverticulum around the base of the mesentery. So resection of gangrenous segment of small intestine along with Meckel's diverticulum and ileo-ileal anastomosis was done. "Intestinal obstruction is frequent complication and is observed in 20-25% of all symptomatic Meckel's diverticulum in adults" [1,2,3,8]. To our best of knowledge only 4-5 similar cases have been reported in the literature [9,10].

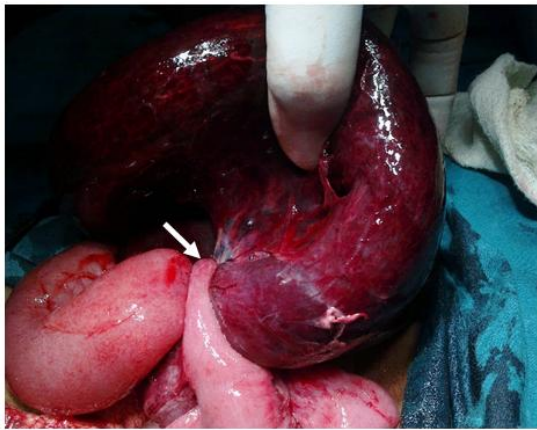


Fig. 1. Intra operative photographs Showing obstruction of the ileal segment and a loop formed by the MD

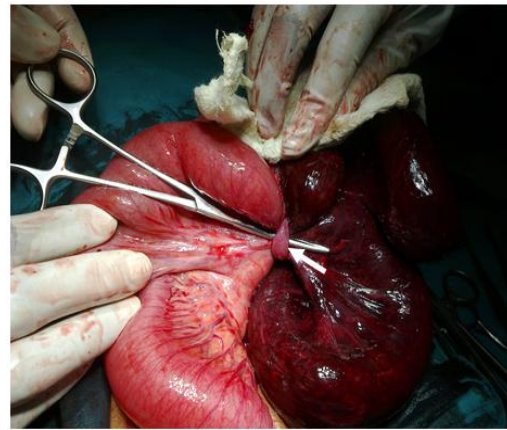


Fig. 2. Intra operative photographs Showing pedunculated Meckel's diverticulum having a stalk

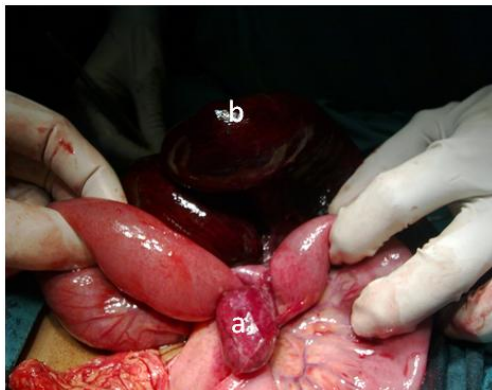

Fig. 3. Intra operative photographs Showing a- looping of MD on small bowel and tip attached to mesentery, b- Small bowel gangrene

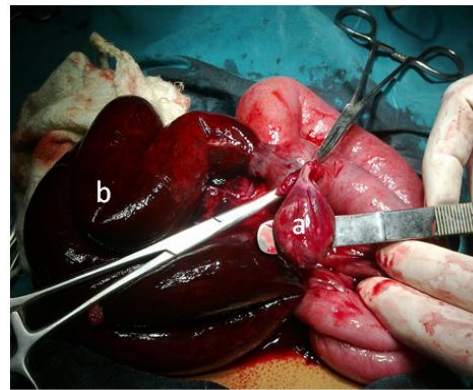


Fig. 4. Intra operative photographs Showing a- pedunculated Meckel's diverticulum size 3x2 cm. b- small bowel gangrene

4. CONCLUSION

Surgical resection has always been the treatment of choice in symptomatic Meckel's diverticulum. The stranded treatment is definitive surgery, including diverticulectomy or ileal resection. Early surgery is required in order to prevent strangulation and gangrene, which reduces the morbidity and mortality.

CONSENT

As per international standard or university standard, patient(s) written consent has been collected and preserved by the author(s).

ETHICAL APPROVAL

As per international standard or university standard written ethical approval has been collected and preserved by the author(s).

COMPETING INTERESTS

Authors have declared that they have no known competing financial interests or non-financial interests or personal relationships that could have appeared to influence the work reported in this paper.

REFERENCES

1. Bhattarai HB, Bhattarai M, Shah S, et al. Meckel's diverticulum causing acute intestinal obstruction: A case series. Clin Case Rep. 2022;10:e06518. DOI: 10.1002/ccr3.6518
2. Runyowa, Martin & Samaraee, Ahmad & Rajagopa, Ramesh & Kalbassi, Mohammed & Bhattacharya, Vish. Unusual case of small bowel strangulation due to

- Meckel's diverticulum. American Journal of Case Reports. 2009;10:9-11.
DOI:10.12659/AJCR.869560.
3. Shilpi Singh Gupta, Onkar Singh. Loop formation of Meckel's diverticulum causing small bowel obstruction in adults: report of two cases, Turkish Journal of Trauma & Emergency Surgery.
DOI: 10.5505/tjtes.2011.54533
 4. Skarpas A, Siaperas P, Zoikas A, Griva E, Kyriazis I, Velimezis G, Karanikas I. Meckel's Diverticulitis. A rare cause of small bowel obstruction. J Surg Case Rep. 2020 Sep 30;2020(9):rjaa339.
DOI: 10.1093/jscr/rjaa339.
PMID: 33024533
PMCID: PMC7524604.
 5. Al Jabri KA, El Sherbini A. Small Bowel Obstruction due to Meckel's Diverticulum: A Case Report. Oman Med J. 2012; 27(1):e029.
DOI: 10.5001/omj.2012.18. Retraction in: Oman Med J. 2020 Jul 12;35(4):e148.
PMID: 28861183; PMCID: PMC5563914.
 6. Prall RT, Bannon MP, Bharucha AE. Meckel's diverticulum causing intestinal obstruction. Am J Gastroenterol. 2001; 96:3426-7.
[PubMed] [Google Scholar]
 7. Higaki S, Saito Y, Akazawa A, Okamoto T, Hirano A, Takeo Y, et al.. Bleeding Meckel's diverticulum in an adult. Hepatogastroenterology 2001;48:1628-30.
[PubMed] [Google Scholar]
 8. Ludtke FE, Mende V, Kohler H, et al. Incidence and frequency of complications and management of Meckel's diverticulum. Surg Gynecol Obstet. 1989;169:537-542.
[PubMed]
 9. Foster NM, McGory ML, Zingmond DS, Ko CY. Small bowel obstruction: a population-based appraisal. J Am Coll Surg. 2006. Aug;203(2):170-176.
DOI:10.1016/j.jamcollsurg.2006.04.020
 10. Gamblin TC, Glenn J, Herring D, McKinney WB. Bowel obstruction caused by a Meckel's diverticulum enterolith: A case report and review of the literature. Curr Surg 2003;60(1):63-64.
DOI:10.1016/S0149-7944(02)00650-5

© 2023 Jatal et al.; This is an Open Access article distributed under the terms of the Creative Commons Attribution License (<http://creativecommons.org/licenses/by/4.0>), which permits unrestricted use, distribution, and reproduction in any medium, provided the original work is properly cited.

Peer-review history:

The peer review history for this paper can be accessed here:

<https://www.sdiarticle5.com/review-history/101854>