

## **Parathyroid Carcinoma: Case Series and Literature Review**

**Emad Rezkallah<sup>1\*</sup>, Andrew Elsaify<sup>2</sup>, George Eskandar<sup>3</sup> and Wael Elsaify<sup>1</sup>**

<sup>1</sup>General Surgery Department, James Cook University Hospital, England.

<sup>2</sup>Medical School, Misr University for Science and Technology, Egypt.

<sup>3</sup>Vascular Surgery Department, James Cook University Hospital, England.

### **Authors' contributions**

*This work was carried out in collaboration among all authors. All authors read and approved the final manuscript.*

### **Article Information**

#### Editor(s):

(1) Dr. Lomas Kumar Tomar, National University of Ireland, Ireland.

#### Reviewers:

(1) Jesse A. Stoff, Integrative Medicine of New York, USA.

(2) Christopher Ekwunife, Federal Medical Centre Abeokuta, Nigeria.

(3) Navin Rudolph, Epworth HealthCare, Australia.

Complete Peer review History: <https://www.sdiarticle4.com/review-history/73145>

**Case Report**

**Received 22 June 2021**  
**Accepted 02 September 2021**  
**Published 07 September 2021**

### **ABSTRACT**

**Background:** Parathyroid carcinoma (PC) is an extremely rare tumor with estimated prevalence of about 0.005% of all cancer cases. There is no established etiology for parathyroid carcinoma; with both environmental and genetic factors may be contributing. The majority of the cases present with manifestations of hypercalcemia, with the diagnosis made only after surgery.

**Methods:** We represent three cases of parathyroid carcinoma who were operated in our surgical department. We retrospectively collected the clinical data associated with the course of presentation, investigations and management of the three patients. We followed-up the three patients for five years post-operatively.

**Case Reports:** Two patients were males (53 years of age) and one female (23 years of age). They all presented with clinical manifestations of hypercalcemia. Ultrasonography and MIBI scans were utilized to localize the tumor but could not differentiate between benign and malignant glands. Malignancy was confirmed only after surgery. No recurrence was detected in five years of follow-up.

**Conclusion:** The diagnosis of parathyroid carcinoma is usually challenging with no single test

could differentiate benign from malignant tumors. Because of the rarity of the disease, more future studies would be required to expand our knowledge regarding the underlying genetic causes which would help to design accurate and reliable diagnostic and therapeutic tools.

**Keywords:** Parathyroid carcinoma; presentation; PTH; diagnosis; recurrence.

## 1. INTRODUCTION

Parathyroid carcinoma is a rare endocrine malignancy which accounts for about 0.005% of all cancer cases reported to the National Cancer Database (NCDB) during the period from 1985 and 1995 [1]. The disease usually occurs during the fifth decade of life. Unlike primary hyperparathyroidism where there is a female preponderance, there is no sex predilection for parathyroid cancer [2]. The overall 5- and 10-year survival rates were 85.5 and 49.5%, respectively, according to the NCDB case series. The most important prognostic factors include tumor size, gender, age at diagnosis, nodal status and extent of tumor resection. Studies proved that tumor size, age at diagnosis, male sex, positive nodal status, and complete tumor resection had hazard ratios for death of 1.02 (1.01–1.02,  $p < 0.0001$ ), 1.06 (1.05–1.07,  $p < 0.0001$ ), 1.67 (1.24–2.25,  $p = 0.0008$ ), 1.25 (0.57–2.76,  $p = 0.6$ ), and 0.42 (0.22–0.81,  $p = 0.01$ ), respectively [3]. The main causes of morbidity and mortality are the consequences of the uncontrolled chronic hypercalcemia rather than the tumor burden. There is no definite underlying etiology for parathyroid carcinomas; it seems to be a result of a complex interaction of environmental and genetic factors. Parathyroid carcinoma may occur either sporadically or as part of a genetic syndrome like multiple endocrine neoplasia type 1, 2A and isolated familial hyperparathyroidism. In addition, parathyroid carcinoma has been reported in 15% of the patients with hyperparathyroidism jaw tumor syndrome [4]. Moreover, prior neck radiation and end-stage renal disease have been associated with an increased risk of parathyroid cancer [5]. Although parathyroid carcinoma is responsible for less than 1% of all cases of primary hyperparathyroidism (pHPT) [6], the majority of the patients present with symptoms of hyperparathyroidism, including severe hypercalcemia, an elevated serum parathyroid hormone (PTH) level, nephrolithiasis or nephrocalcinosis, osteopenia, gastrointestinal disturbances, depression, fatigue and/or memory disturbance. The diagnosis of parathyroid carcinoma is usually challenging. In the absence of metastatic disease, the differentiation between

benign and malignant disease is difficult [7]. Most of the imaging studies (ultrasound, CT scan, MRI and PET-CT) cannot differentiate between adenoma and parathyroid carcinoma. However, Computed tomography (CT) with contrast can provide excellent details on the location of the lesion and its relation with the adjacent structures [8].

Magnetic resonance imaging (MRI) with gadolinium and fat suppression can give more accurate details on soft tissues of the neck. Additionally, Technetium-99m sestamibi is a lipophilic isotope that is taken up by abnormal parathyroid tissue and despite having a limited role in the differentiation between benign and malignant parathyroid lesions, can be useful in the diagnosing and localization of metastatic parathyroid carcinoma [9]. Fine needle aspiration cytology (FNAC) is not recommended because of the significant probability of false negative results and the possibility of disruption of the neoplastic capsule with subsequent neoplastic spread, leading to higher chances of recurrence. However, it may be valuable in distinguishing thyroid from parathyroid tissue and to identifying metastatic parathyroid carcinomas. The most effective management of parathyroid carcinoma is surgery. *En bloc* dissection of the tumor with the thyroid lobe, the ipsilateral parathyroid and any other affected tissue provides the most suitable treatment with the best prognosis. It is essential during surgery to avoid damaging the tumor capsule, as any residual or dispersed cells could lead to tumor recurrence.

In the current study, we represent three cases of parathyroid carcinoma who were operated in our general surgery in addition to providing brief review of the current literature.

## 2. METHODS

We carried out a retrospective review of three patients who were diagnosed with parathyroid carcinomas in our general surgery department during the period from 2011 to 2021. The patients data were obtained from the hospital recording system. 338 patients had parathyroid surgery during that period; three of them had

parathyroid carcinoma. Initial assessment included history taking, clinical examination and ultrasound scan. No biopsy was performed according to the guidelines. All patients had MIBI scan. Every separate case was discussed at an endocrine MDT meeting involving an endocrine surgeon, endocrinologist, anesthetist, radiologist and pathologist. Our findings were compared to the available literature. We followed-up our patients for five years post-surgery.

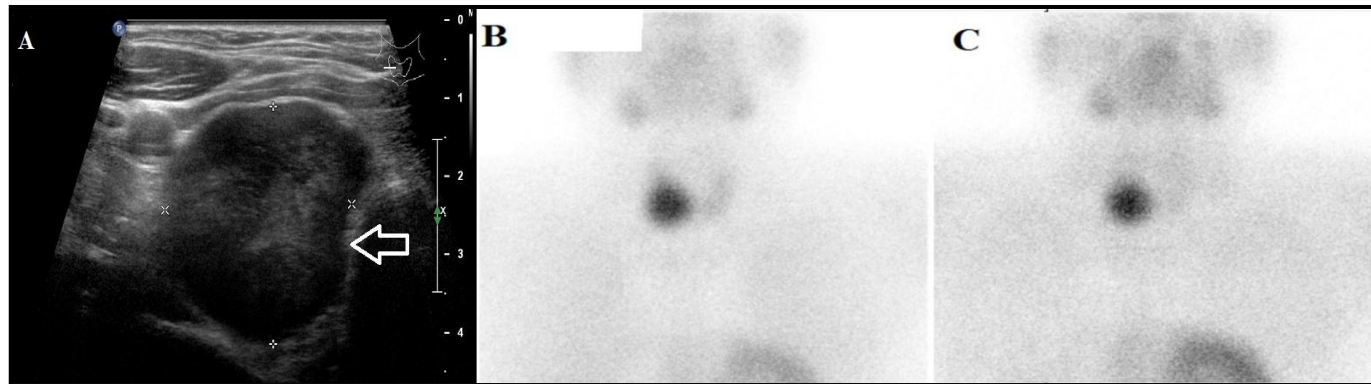
### 3. CASE REPORTS

Three cases have been diagnosed with parathyroid carcinoma in our general surgery department. Two patients were males and one was female. Two of them were diagnosed at the age of 53 and one at the age of 23. All of them presented with manifestation of hypercalcemia; one of them had a history of renal calculi. The three patients had highly elevated pre-operative PTH ( $\geq 140$  ng/L) and serum calcium levels ( $\geq 3$  mmol/L) associated with low 25OH-Cholecalciferol level ( $\leq 53$  nmol/L). All patients had initial evaluation by ultrasound scan, which

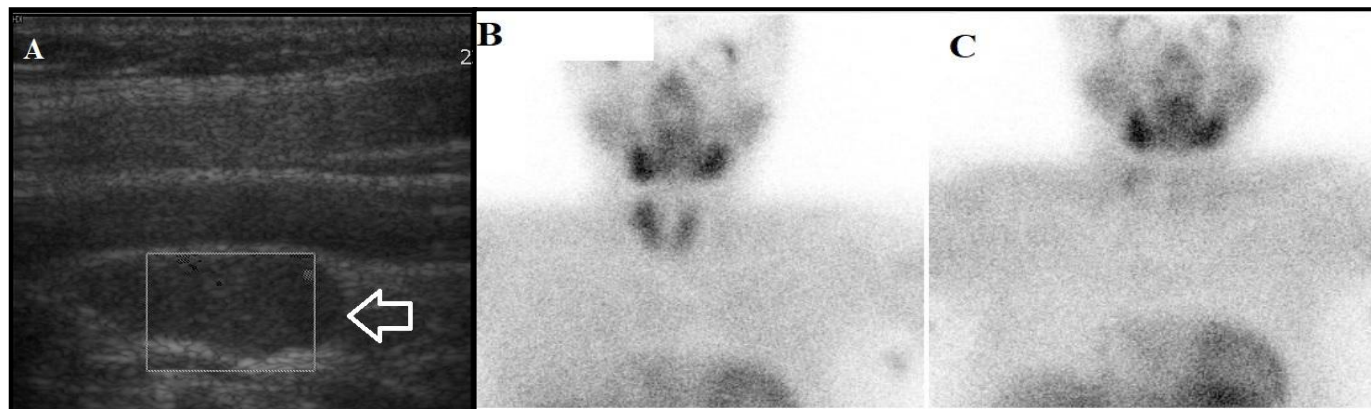
suggested right inferior parathyroid adenomas in two of them and a right ectopic parathyroid gland posterior to right common carotid artery in the last one. The three patients had MIBI scan which suggested parathyroid adenomas in 2 of them with equivocal results in the third one. The three patients had initial minimal invasive parathyroidectomy; the first patient had involved margins and was re-submitted for en-block resection of the right thyroid lobe, strap muscles and right level  $\epsilon$  lymph node, the 2nd patient had excision of the right superior and inferior parathyroid glands; parathyroid malignancy was found in the right inferior gland, and the third patient had excision of the ectopic right parathyroid gland (Figs. 1 and 2). Microscopic features that confirmed the diagnosis of parathyroid carcinoma include the potential large size of the tumor, the increased mitotic activity in addition to the capsular and vascular invasion. No residual malignancy was found. The three patients had post-operative regular follow-ups with frequent assessment of the PTH and calcium levels. No recurrence was detected on five-years of follow-up.

**Table 1. Patients demographics and characteristics**

	<b>Case 1</b>	<b>Case 2</b>	<b>Case 3</b>
<b>Age</b>	<b>53</b>	<b>53</b>	<b>23</b>
Gender	Male	Male	Female
Pre-operative PTH level	262 ng/L	140 ng/L	148 ng/L
Pre-operative Calcium	3.01 mmol/L	3 mmol/L	3.17 mmol/L
Preoperative 25OH-Cholecalciferol	53.1 nmol/L	53.6 nmol/L	31 nmol/L
Clinical presentation	Hypercalcemia	Hypercalcemia and renal calculi	Hypercalcemia
Ultrasonography	A 3 cm hypo echoic lesion in the right inferior lobe of the thyroid	A 19x9 mm right lower parathyroid lesion	A 24 x 11 x 8 mm ectopic parathyroid gland posterior to the right common carotid artery
MIBI scan	Right inferior parathyroid adenoma	Equivocal results	Ectopic parathyroid adenoma
Operation	Initial right inferior parathyroidectomy Re-surgery: excision of the right thyroid lobe, strap muscles and level $\epsilon$	Right superior and inferior parathyroidectomy	Right thyroid nodule and right parathyroidectomy
5 years follow-up	No recurrence	No recurrence	No recurrence



**Fig. 1. (A) Ultrasonography showing a 3 cm hypoechoic lesion deep to the right inferior lobe of thyroid which appears separate from the right lobe of thyroid and compressing the edge. (B) and (C) MIBI scan showing a large focal area of increased uptake over the right lower pole thyroid region, consistent with a massive right inferior parathyroid adenoma**



**Fig. 2. (A) Ultrasonography showing a 24 x 11 x 8 mm ovoid ectopic parathyroid immediately posterior to the mid-right common carotid artery, lateral to the thyroid. (B) and (C) MIBI scan showing faint retained activity projected through the lateral aspect of right upper/mid thyroid which corresponds to an ectopic location of the parathyroid gland posterior to the carotid and jugular vessels**

#### 4. LITERATURE REVIEW

Parathyroid carcinoma (PC) is a rare endocrine malignancy with less than 1000 recorded cases reported in the literature since the first case described by de Quervain in 1904 [10]. Parathyroid carcinoma accounts for about 0.5–5% of all cases of primary hyperparathyroidism (PHPT) [11]. There is no gender dominance associated with PC and the mean age of diagnosis is 45-51 years<sup>(1)</sup>. The exact etiology of PC is unknown and may be attributed to both genetic and environmental factors. Some studies have reported an increased risk of parathyroid carcinoma in patients with history of neck radiation, adenoma, secondary and tertiary hyperparathyroidism [12]. Genetic syndromes associated with parathyroid carcinoma may include multiple endocrine neoplasia type 1, 2A, isolated familial hyperparathyroidism and hyperparathyroidism jaw tumor syndrome [12-16]. Several genetic mutations have been implicated in the pathogenesis of parathyroid carcinomas such as HRPT2 (CDC73, or Parafibromin) gene, retinoblastoma (Rb), p53, breast carcinoma susceptibility (BRCA2) and cyclin D1/parathyroid adenomatosis gene 1 (PRAD1) genes [11].

Approximately, 90% of parathyroid carcinoma patients present initially with manifestations of hypercalcemia [17]. On the other hand, less than 10% of parathyroid carcinoma cases are nonfunctional. The main clinical manifestations include depression, anxiety, weight loss, weakness, bone disease, renal involvement, abdominal pain, and peptic ulcer disease. Skeletal involvement includes osteopenia, bone pain, osteoporosis, osteofibrosis and pathologic fractures. Renal manifestations like nephrolithiasis and renal insufficiency are frequently present [18]. About 50% of patients may present with a palpable neck mass related to either an advanced local or regional metastatic disease. Obara et al. [19] summarized the clinical criteria for suspicion of malignant parathyroid neoplasm as: 1- age below 55 years, 2- marked hypercalcaemia and hyperparathormonaemia, 3- severe bone symptoms and kidney symptoms, 4- recurrent laryngeal paralysis due to tumor invasion, and 5- palpable cervical swelling, that is rare in benign disease. Serum calcium levels are frequently higher than 14 mg/dL and PTH serum levels are usually 3 to 10 times higher than the upper limit of normal [20]. Plasma levels of alkaline phosphatase and  $\alpha$  and  $\beta$  subunits of human chorionic gonadotrophin are usually

raised [21]. Clinical and radiological differentiation between benign and malignant parathyroid is usually challenging. Ultrasonography is usually the initial imaging used for the evaluation of any neck mass. Sonographic features that raise the suspicion of parathyroid malignancy may include a lobulated, hypoechoic gland with relatively large and ill-defined borders when compared to adenomas, local infiltration, calcification, suspicious vascularity, thick capsule, lymph node enlargement and invasion of the tumor to adjacent structures [22]. Technetium-99m sestamibi scintigraphy is another imaging modality that can be useful in the diagnosis and localization of ectopic hyperfunctioning tissue and metastatic disease; however, it cannot differentiate benign from malignant cases [23]. Other investigations like CT, MRI and PET-CT scans although lack sensitivity in detecting parathyroid carcinoma, they can provide more accurate details on the location of the lesion, its relation with other structures and the lymph node involvement [24]. The sensitivity of ultrasonography, 99mTc sestamibi scan, CT and MRI for localizing parathyroid carcinoma in the neck were, 83%, 79%, 69% and 93%, respectively [25]. Some studies have proven high sensitivity of selective venous catheterization with PTH measurement in localizing functioning parathyroid tissue; however, it is an invasive study and not commonly available, being recommended only when other noninvasive studies fail to localize the disease. Fine-needle aspiration cytology is not recommended because cytological discrimination between malignant and benign disease is difficult in addition to the risk of disrupting the tumor capsule with subsequent spread of the tumor cells [26].

Intraoperative findings that suggest malignancy include irregular, firm to hard mass, being large grayish to white in color; 3cm or more and adherent to or infiltrating the adjacent structures. Histopathological features of parathyroid carcinoma and adenoma are similar. Morphologic features that may suggest parathyroid carcinoma include fibrous bands with a trabecular architecture (90%), capsular invasion (60%), vascular invasion (15%) and mitotic activity (80%) [27]. However, in the absence of vascular invasion, perineural invasion, invasion to adjacent structures and metastasis, none of above criteria is sufficiently sensitive or specific to confirm or discard the diagnosis [28]. Recently, molecular biomarkers

have been utilized to distinguish parathyroid carcinoma from adenomas. Immunohistochemical positivity for galectin-3, overexpression of p53, and increased Ki67 proliferation index (> 5%) are implied to confirm malignancy in parathyroid tumor [29]. Other immunohistochemical (IHC) biomarkers used for the diagnosis of PC include parafibromin (encoded by the CDC73/HRPT2 gene) and PGP9.5 (encoded by ubiquitin carboxyl-terminal esterase L1 (UCHL1)). Studies have shown that strong staining for PGP9.5 had a sensitivity of 78% for the detection of parathyroid carcinoma and a specificity of 100%, while complete lack of nuclear parafibromin staining had a sensitivity of 67% and a specificity of 100% [30].

Complete en-bloc resection of the tumour provides the best chance for cure. As it is possible to encounter both adenoma and carcinoma synchronously, a formal exploration of all the four glands should be performed [31]. Most studies recommend en bloc resection of the tumor together with the ipsilateral thyroid lobe, and excision of any involved adjacent structures, at the time of the initial surgery to obtain the best local disease control and improve survival [2]. It is essential not to rupture the capsule of the tumor and spill the tumor cells in the field. The extent of lymphadenectomy is still a matter of debate. While many authors suggest compartmental dissection only in case of clinically involved lymph nodes and discouraging a prophylactic dissection that has not been proven to improve survival but increases the morbidity [32,33], other authors recommend routine central neck dissection, stating that it is involved by nodal metastases in up to 10% of patients [34].

In the immediate postoperative period, close monitoring of the calcium levels and adequate replacement is necessary to avoid severe hypocalcaemia due to the hungry bone syndrome. After surgery, if the patient is normocalcaemic, PTH levels are within normal limits with no evidence of extensive vascular or capsular invasion; the patient will need close monitoring only [35]. Otherwise, if the patient continues to be symptomatic, PTH levels remain elevated or there is extensive evidence of vascular and capsular invasion, re-operation can be beneficial [36]. It was reported that patients who were diagnosed before or during surgery, and had an en-bloc resection, had a recurrence rate of 33%, while patients who were diagnosed after initial surgery had a local recurrence rate of

more than 50% [37]. The most common sites of disease dissemination are the regional lymph nodes followed by the lungs, bones and liver. Patients with residual or recurrent disease usually present with gradually increasing PTH and serum calcium levels. The treatment strategy consists of controlling hypercalcaemia, localising studies and surgical excision of resectable diseases when feasible [38]. Removal of all functioning tumour tissue gives the most effective relief of symptoms [39]. In the past, radiotherapy was not deemed effective in the treatment of parathyroid carcinoma; however, recent studies have reported lower recurrence and longer disease-free survival with the use of adjuvant radiotherapy [40,41]. Cytotoxic chemotherapy is less commonly used for parathyroid cancer to reduce the tumor burden [42]. Several classes of calcium lowering drugs have been used to reduce the serum calcium level with transient results lasting for only a few days including mitramycin, intravenous bisphosphonates, and calcitonin in combination with glucocorticoid [43]. The new drugs such as the calcimimetics have been introduced as more effective at lowering the serum calcium and PTH levels with lesser side effects [44].

Parathyroid carcinoma usually has a slow progressive course. Patients who undergo complete en-bloc tumour resection can have survival rates as high as 90% in five years and 67% in 10 years [45]. Negative prognostic factors include lymph node involvement at the time of diagnosis, distant metastases and non-functioning carcinomas [2]. Most recurrences will manifest in the first three years [46].

The aim of follow-up is early detection of potentially curable loco-regional recurrence and/or secondary tumours. This should include clinical examination with calcium levels and PTH monitored every three months for the first three years, then every six months till fifth year and yearly lifelong after that. Any suspicion for recurrence should be confirmed with imaging studies [11].

## 5. DISCUSSION

Parathyroid carcinoma (PC) is a rare endocrine malignancy [10]. It is estimated that it is responsible for about 0.5–5% of all cases of primary hyperparathyroidism (pHPT) [11]. Studies reported that the disease has no gender dominance, and the mean age of diagnosis is 45-51 years [1]. However, we reported three patients

in our study; two of them were males and one was female. In addition, two of them were diagnosed at the age of 53 and the third one was diagnosed at the age of 23. Parathyroid carcinoma can occur either sporadically or in association with other genetic syndromes like multiple endocrine neoplasia type 1, 2A, isolated familial hyperparathyroidism and hyperparathyroidism jaw tumor syndrome [12-16]. No one of our patients had underlying genetic abnormality. It was reported that more than 90% of parathyroid carcinoma patients present initially with manifestations of hypercalcemia [17]. Our three patients presented with manifestation of hypercalcemia; one of them had also a history of renal calculi. The clinical criteria for suspicion of malignant parathyroid neoplasm have been summarized by Obara et al. [19]; all our three patients were diagnosed before the age of 55 and presented with high levels of parathyroid hormone and calcium with clinical manifestations of hypercalcemia in addition to low levels of 25OH – Cholecalciferol. All our patients had initial imaging of ultrasonography and MIBI scan. In two patients, the MIBI scan was consistent with parathyroid adenoma, while it had equivocal results in the third one. Parathyroid biopsy was not recommended, thus none of our patients had pre-operative FNAC. Malignancy was confirmed only after surgery. Microscopic features that were suggesting malignancy included the relatively large size of the tumor, infiltration of the adjacent structures, high mitotic figures, capsular or vascular invasion and the presence of increased Ki67 proliferation index (>5%). Two of our patients had parathyroid gland excision only with clear margins, while the third one had involved margins which indicated further resection of the ipsilateral thyroid lobe, strap muscles and level  $\varepsilon$  lymph nodes. All our patients had regular evaluation of the serum PTH and calcium levels. All of them had normal PTH levels over 5 years of follow-up with no evidence of any recurrent disease.

## 6. CONCLUSION

Parathyroid carcinoma is a rare malignancy which affects both men and women. Most patients present with complications of hypercalcemia. The main causes are unknown. Differentiation between benign and malignant disease is usually challenging on tissue specimens. Complete surgical resection at the time of first operation provides the best chance of cure. Recurrence is common and multiple resections may be indicated to reduce the tumor

burden. More multi-institutional, multidisciplinary researches are needed to assist in understanding of the genetic causes of parathyroid carcinoma, to establish more reliable tools for diagnosis, management and follow-up.

## CONSENT

As per international standard or university standard, Participants' written consent has been collected and preserved by the author(s).

## ETHICAL APPROVAL

It is not applicable.

## COMPETING INTERESTS

Authors have declared that no competing interests exist.

## REFERENCES

1. Hundahl SA, et al. Two hundred eighty-six cases of parathyroid carcinoma treated in the U.S. between 1985-1995: a National Cancer Data Base Report. The American College of Surgeons Commission on Cancer and the American Cancer Society. *Cancer*. 1999;86(3):538–44.
2. Koea Jonathan B., Shaw James H.F. Parathyroid cancer: Biology and management. *Surg. Oncol*. 1999;8:155–165.
3. Asare EA, Sturgeon C, Winchester DJ, et al. Parathyroid Carcinoma: An Update on Treatment Outcomes and Prognostic Factors from the National Cancer Data Base (NCDB). *Ann Surg Oncol*. 2015;22:3990–3995.
4. Chen JD, Morrison C, Zhang C, Kahnoski K, Carpten JD, Teh BT. Hyperparathyroidism-jaw tumour syndrome. *J. Intern. Med*. 2003;253:634–642. DOI: 10.1046/j.1365-2796.2003.01168.x
5. Ireland JP, Fleming SJ, Levison DA, Cattell WR, Baker LR. Parathyroid carcinoma associated with chronic renal failure and previous radiotherapy to the neck. *J. Clin. Pathol*. 1985;38:1114-1118.
6. Shane E. Parathyroid carcinoma. *J. Clin. Endocrinol. Metab*. 2001;86(2):485–493
7. Sharretts JM, Kebebew E, Simonds WF. Parathyroid Cancer. *Semin. Oncol*. 2010;37:580–590.

- DOI: 10.1053/j.seminoncol.2010.10.013.
8. Stark DD, Gooding GA, Moss AA, Clark OH, Ovenfors CO. Parathyroid imaging: comparison of high-resolution CT and high-resolution sonography. *AJR Am. J. Roentgenol.* 1983;141:633e638.
  9. S. Al-Sobhi L.H. Ashari S. Ingemansson. Detection of metastatic parathyroid carcinoma with Tc-99m sestamibi imaging. *Clin Nucl Med.* 1999;24:21e3; A. Al-Kurd et al./*Surgical Oncology.* 2014;23:107e114.
  10. Quervain Fd. Parastruma maligna aberrata. *Deutsche Zeitschrift Fuer Chirurgie.* 1904;100:334–52.
  11. Givi B, Shah JP. Parathyroid carcinoma. *Clin Oncol (R Coll Radiol).* 2010;22(6): 498–507.
  12. McMullen T, Bodie G, Gill A, Ihre-Lundgren C, Shun A, Bergin M, Stevens G, Delbridge L. Hyperparathyroidism after irradiation for childhood malignancy. *Int. J. Radiat. Oncol.* 2009;73:1164–1168.  
DOI: 10.1016/j.ijrobp.2008.06.1487.
  13. Bradley KJ, et al. Uterine tumours are a phenotypic manifestation of the hyperparathyroidism-jaw tumour syndrome. *J Intern Med.* 2005;257(1):18–26.
  14. Simonds WF, et al. Familial isolated hyperparathyroidism: clinical and genetic characteristics of 36 kindreds. *Medicine (Baltimore).* 2002;81(1):1–26.
  15. Jenkins PJ, et al. Metastatic parathyroid carcinoma in the MEN2A syndrome. *Clin Endocrinol.* 1997;47(6):747–51.
  16. Del Pozo C, et al. Parathyroid carcinoma in multiple endocrine neoplasia type 1. Case report and review of the literature. *Hormones (Athens).* 2011;10(4):326–31.
  17. Wei CH, Harari A. Parathyroid carcinoma: update and guidelines for management. *Curr Treat Options in Oncol.* 2012;13(1): 11–23
  18. A. Schantz, B. Castleman Parathyroid carcinoma. A study of 70 cases *Cancer*, 31 (3) (1973), p. 600–5. 30. Rodgers SE, Perrier ND. Parathyroid carcinoma. *Curr Opin Oncol.* 2006;18(1):16–22.  
DOI:10.1002/1097  
0142(197303)31:3<600::AID  
CNCR2820310316>3.0.CO;2–0
  19. Obara T, Fujimoto Y. Diagnosis and treatment of patients with parathyroid carcinoma: an update and review. *World J. Surg.* 1991;15:738–744.
  20. Dudney WC, Bodenner D, Stack Jr BC. Parathyroid carcinoma. *Otolaryngol Clin North Am.* 2010;43(2):441-453.  
DOI: 10.1016/j.otc.2010.01.011
  21. Rubin MR, Bilezikian JP, Birken S, Silverberg SJ. Human chorionic gonadotropin measurements in parathyroid carcinoma. *Eur. J. Endocrinol.* 2008;159: 469–474
  22. Hara H, Igarashi A, Yano Y, et al. Ultrasonographic features of parathyroid carcinoma. *Endocr J.* 2001;48(2):213-217.  
DOI: 10.1507/endocrj.48.213
  23. Patel CN, Salahudeen HM, Lansdown M, Scarsbrook AF. Clinical utility of ultrasound and 99mTc sestamibi SPECT/CT for preoperative localization of parathyroid adenoma in patients with primary hyperparathyroidism. *Clin Radiol.* 2010;65 (4):278-287.  
DOI: 10.1016/j.crad.2009.12.005
  24. Stark DD, Gooding GA, Moss AA, Clark OH, Ovenfors CO. Parathyroid imaging: comparison of high-resolution CT and high-resolution sonography. *AJR Am. J. Roentgenol.* 1983;141:633e638.
  25. Simonds WF. Parathyroid cancer and the CDC73 tumor suppressor gene. *Int J Endocr Oncol.* 2014;1:59-69.  
DOI: 10.2217/ije.14.2
  26. Thompson SD, Prichard AJ. The management of parathyroid carcinoma. *Curr. Opin. Otolaryngol. Head Neck Surg.* 2004;12 93e7.14.
  27. Wei CH, Harari A. Parathyroid carcinoma: Update and guidelines for management. *Curr Treat Options Oncol.* 2012;13(1):11-23.  
DOI: 10.1007/s11864-011-0171-3
  28. Duan K, Mete O. Parathyroid carcinoma: diagnosis and clinical implications *Turk Patoloji Derg.* 2015;31(Suppl. 1):80-97.  
DOI: 10.5146/tjpath.2015.01316
  29. Erovcic BM, Harris L, Jamali M, et al. Biomarkers of parathyroid carcinoma. *Endocr Pathol.* 2012;23(4):221-231.  
DOI: 10.1007/s12022-012-9222-P
  30. Viive M. Howell, Anthony Gill, Adele Clarkson, Anne E. Nelson, Robert Dunne, Leigh W. Delbridge, Bruce G. Robinson, Bin T. Teh, Oliver Gimm, Deborah J. Marsh, accuracy of combined protein gene product 9.5 and parafibromin markers for immunohistochemical diagnosis of parathyroid carcinoma. *The Journal of Clinical Endocrinology & Metabolism.* 2009;94(2):434–441.



31. Dionisi S, Minisola S, Pepe J. Concurrent parathyroid adenomas and carcinoma in the setting of multiple endocrine neoplasia type 1: presentation as hypercalcemic crisis. *Mayo Clin. Proc.* 2002;77:866e869.
32. Hsu KT, Sippel RS, Chen H, Schneider DF. Is central lymph node dissection necessary for parathyroid carcinoma? *Surgery.* 2014;156(6):1336-1341, Discussion 1341
33. Kebebew E. Parathyroid carcinoma. *Curr. Treat. Options Oncol.* 2001;2(4):347-354.
34. Schulte KM, Talat N, Miell J, Moniz C, Sinha P, Diaz-Cano S. Lymph node involvement and surgical approach in parathyroid cancer. *World J. Surg.* 2010; 34(11):2611-2620.
35. Fujimoto Y, Obara T, Ito Y, Kodama T, Nobori M, Ebihara S. Localization and surgical resection of metastatic parathyroid carcinoma. *World J Surg.* 1986;10:539–547.
36. Shane E. Clinical review 122: parathyroid carcinoma. *J Clin Endocrinol Metab.* 2001; 86:485–493.
37. Kebebew E. Parathyroid carcinoma. *Curr Treat Options Oncol.* 2001;2:347–354.
38. Obara T, Fujimoto Y. Diagnosis and treatment of patients with parathyroid carcinoma: an update and review. *World J. Surg.* 1991;15:738–744.
39. Kebebew E, Arici C, Duh QY, Clark OH. Localization and reoperation results for persistent and recurrent parathyroid carcinoma. *Arch Surg.* 2001;136:878–885.
40. Chow E, Tsang RW, Brierley JD, Filice S. Parathyroid carcinoma – the Princess Margaret Hospital experience. *Int J Radiat Oncol Biol Phys.* 1998;41:569–572.
41. Munson ND, Foote RL, Northcutt RC, et al. Parathyroid carcinoma: is there a role for adjuvant radiation therapy? *Cancer.* 2003; 98:2378–2384
42. Shane E. Parathyroid Carcinoma. *J. Clin. Endocrinol. Metab.* 2001;86:485–493. DOI: 10.1210/jcem.86.2.7207
43. Shane E. Clinical review 122: parathyroid carcinoma. *J Clin Endocrinol Metab.* 2001; 86(2):485–93.
44. Silverberg SJ, Rubin MR, Faiman C, et al. Cinacalcet hydrochloride reduces the serum calcium concentration in inoperable parathyroid carcinoma. *J Clin Endocrinol Metab.* 2007;92(10):3803–8.
45. Kleinpeter KP, Lovato JF, Clark PB, Wooldridge T, Norman ES, Bergman S, Perrier ND. Is parathyroid carcinoma indeed a lethal disease? *Ann Surg Oncol.* 2005;12(3):260-6. DOI: 10.1245/ASO.2005.03.036. Epub 2005 Mar 3. PMID: 15827819.
46. Sandelin K, Tullgren O, Farnebo LO. Clinical course of metastatic parathyroid cancer. *World J Surg.* 1994;18:594–598.

© 2021 Rezkallah et al.; This is an Open Access article distributed under the terms of the Creative Commons Attribution License (<http://creativecommons.org/licenses/by/4.0>), which permits unrestricted use, distribution, and reproduction in any medium, provided the original work is properly cited.

*Peer-review history:*

*The peer review history for this paper can be accessed here:*

<https://www.sdiarticle4.com/review-history/73145>