



Clinical Peripheral Atypical Presentation of Tuberculosis in the Head and Neck Region in Asian Population —11 Years Experience and Review of Literature

**Mayur J. Gawande^{a†}, Rishabh R. Agrawal^{b#}, Parul Nimbalkar^{b#},
Rakshita Nitnaware^{b≡}, Tannu Mishra^{b≡}, Akshay Navdhinge^{b≡},
Dimple Lawhale^{b≡} and Sanjana Pandharkar^{b≡}**

^a Department of Oral & Maxillofacial Surgery, Swargiya Dadasaheb Kalmegh Smruti Dental College & Hospital, Wanadongari Road, Hingana, Nagpur- 440016, M.S, India.

^b Swargiya Dadasaheb Kalmegh Smruti Dental College & Hospital, Wanadongari Road, Hingana, Nagpur- 440016, M.S, India.

Authors' contributions

This work was carried out in collaboration among all authors. 'All authors read and approved the final manuscript.

Article Information

DOI: 10.9734/JPRI/2021/v33i59A34262

Open Peer Review History:

This journal follows the Advanced Open Peer Review policy. Identity of the Reviewers, Editor(s) and additional Reviewers, peer review comments, different versions of the manuscript, comments of the editors, etc are available here: <https://www.sdiarticle5.com/review-history/78623>

Original Research Article

Received 30 November 2021

Accepted 15 December 2021

Published 16 December 2021

ABSTRACT

Tuberculosis TB one of the major health problem in developed countries, with extremely high prevalence in Asian countries, mainly caused by "Mycobacterium Tuberculosis". Although pulmonary tuberculosis is the most common form of the disease, it also can occur in other organ systems such as lymph nodes, central nervous system, skeletal system, hepatic system, and gastrointestinal system, including the oral cavity. Extrapulmonary tuberculosis is an uncommon form of chronic infection that does not present typical signs and symptoms of pulmonary tuberculosis. Oral tuberculosis is an uncommon form and is often overlooked as it shows no pathognomonic signs. This article presents our experience of unusual atypical tuberculosis in the Head and Neck region.

[†]Assistant Professor;

[‡]HOD, & Professor;

[#]General Dentist;

[≡]General & Cosmetic Dentist;

*Corresponding author: E-mail: mayur.gawande@sdk-dentalcollege.edu.in, drmayurgawande@gmail.com;

Keywords: *Extra pulmonary tuberculosis; pulmonary tuberculosis; tuberculosis ulcer; mycobacterium; tuberculosis.*

1. INTRODUCTION

Tuberculosis is described as the "king of diseases" from the Vedas and has been mentioned by Sushruta and Charkas in 600 B.C. Tuberculosis is a chronic communicable disease of worldwide prevalence, caused by "Mycobacterium Tuberculosis" in humans. Robert Koch, a German physician, discovered the tuberculosis bacillus in 1882. It has been a worldwide major health problem for centuries. India accounts for nearly one-third of the global burden of tuberculosis [1]. Although the oral manifestation of tuberculosis has a rare occurrence, it has been considered to account for 1.0-5.0% of all tuberculosis infections. Currently, oral tuberculosis is reappearing alongside much forgotten extra pulmonary tuberculosis as a consequence of the outbreak and emergence of acquired immune deficiency syndrome [2]. This article presents our experience of peripheral atypical presentation of or facial tuberculosis in the head, neck, and face region and a thorough review in an attempt to assess the need for an hour too early diagnosis of clinical manifestations and symptoms of oral tuberculosis.

Dental identification of the tuberculosis lesions has the potential of serving as crucial aid is the first line of control for this dangerous, many times fatal disease. The oral cavity is a very rare location for TB infection. Oral TB lesions can be primary or secondary. Primary oral TB lesions are extremely rare, generally occur in young patients, and are associated with cervical lymphadenopathy. Primary lesions remain painless through the majority of cases and are manifested in immunocompromised conditions e.g. HIV infection) more frequently than their secondary counterpart. Secondary lesions are more common and are mostly seen in older people. The oral manifestations of TB are superficial ulcers, patches, indurate soft tissue lesions, or anytime lesions within the jaw which will be through TB Osteomyelitis or simple bony radiolucency. Of all these oral lesions, the ulcerative form is the most common. Oral lesions of TB are nonspecific in their clinical presentation and many times does consider in Physician diagnosis, especially when oral lesions are present before systemic symptoms become apparent. We discuss our experience of secondary Tuberculosis in the Head and Neck Region [3].

2. MATERIALS AND METHODS

The records of all patients from the Department of Oral and Maxillofacial Surgery at Swargiya Dadasaheb Kalmegh Smruti Dental College and Hospital, Nagpur. The signs and with a histopathological confirmed diagnosis of TB of the head and neck region were surveyed. 21 cases were identified from January 2010 to December 2021. The Criteria for diagnosis of TB were histopathological evidence of granulomatous inflammation with epithelioid cells and Langhans giant cells or acid-fast bacilli seen on Ziehl Neelson staining of biopsy specimens (Fig. 1) The patients' medical records were reviewed for details relating to presenting signs and symptoms, site and appearance of lesions, Chest X-Rays findings and sputum smear and tuberculosis culture results and symptoms, site and appearance of the lesions, chest x-ray findings, and sputum smear and tuberculosis culture.

3. RESULTS

Clinical data relating to 21 patients with histopathological diagnosis of TB of the year 2010 to 2021 our department is summarized in Table 1. Representative pictures demonstrating the clinical and histopathological appearances of oral lesions are shown in Fig. 1. Fourteen cases were 40 years or above (67%) and 7 cases (33%) were 20 years or below. The age of the patients ranged from 9 to 68 with an average 38.8 years (mean \pm SD) and male to female ratio is 9:12. The age of the male patients ranged from 10 to 68 years with an average 38.8 years (mean \pm SD). The age of female patients ranged from 9 to 70 years with an average 40.4 years (mean \pm SD). The clinical symptoms encountered in orofacial tuberculosis are summarized in Table 2. The duration of the symptoms ranges from 1 month to 2.5 years with an average 9.4 month (mean \pm SD). HIV serology data is unavailable for the current patient series. About 12 patients have primary tuberculosis lesions whereas 9 patients had secondary tuberculosis lesions. Intraoral sites includes Buccal Mucosa (2 cases), lower lip (3 cases), dorsum of tongue (2 cases), lateral border of tongue (2 cases), Retromolar Trigone (5 cases), buccal vestibule (2 cases), hard palate (2 cases), unhealed extraction socket (4 cases), Floor of mouth (1 case). The symptoms associated with oral tuberculosis patients summarized in order of frequency in Pie Chart 1.

Table 1. Showing the clinical symptoms encountered in Orofacial Tuberculosis

Patient No.	Year	Age	Sex	Duration of symptoms	Location	Differential diagnosis	Chest Radiograph	Type of TB
1	2010	68	M	10 months	Lower left buccal vestibule	Squamous Cell Carcinoma	N	Primary
2	2010	47	F	1 year	Left Lateral border of tongue	Squamous Cell Carcinoma	N	Primary
3	2010	52	F	1 year	Dorsum of tongue	Squamous Cell Carcinoma	N	Secondary
4	2011	10	F	11 months	Right Retromolar trigone region	Syphilitic Ulcer	NA	Primary
5	2012	9	F	2 month	Right retromolar trigone, unhealed extraction wound	Verrucous Carcinoma	Active	Primary
6	2010	42	M	5 months	Left Buccal mucosa	Chronic Ulcer	N	Secondary
7	2014	49	F	2 years	Retromolar trigone , Hard Palate	Verrucous Cell Carcinoma	Active	Secondary
8	2016	13	M	9 months	Upper right vestibule area	Chronic Ulcer	N	Primary
9	2011	43	M	1 month	Left Unhealed extraction wound with	Squamous Cell Carcinoma	Millet seed like appearance	Secondary
10	2010	19	M	2 years 1 month	Floor of mouth with LN involvement	Benign Salivary Gland tumor	Old TB not active lesion	Secondary
11	2010	60	M	10 months	Lower Lip left side	Sub mental Lymphadenopathy	NA	Primary
12	2010	47	F	4 months	Left Lateral border of tongue with Submandibular LN	Squamous Cell Carcinoma	Active	Primary
13	2010	52	F	9 months	Left buccal mucosa Submandibular LN	Submandibular Lymphadenopathy	N	Primary
14	2011	14	F	1 Year 2 months	Right Retromolar trigone region	Chronic Ulcer	NA	Secondary
15	2011	68	F	3 month	Lower lip & Submental LN	Verrucous Carcinoma	Active	Primary
16	2012	41	M	5 months	Lower lip	Chronic Ulcer	N	Primary

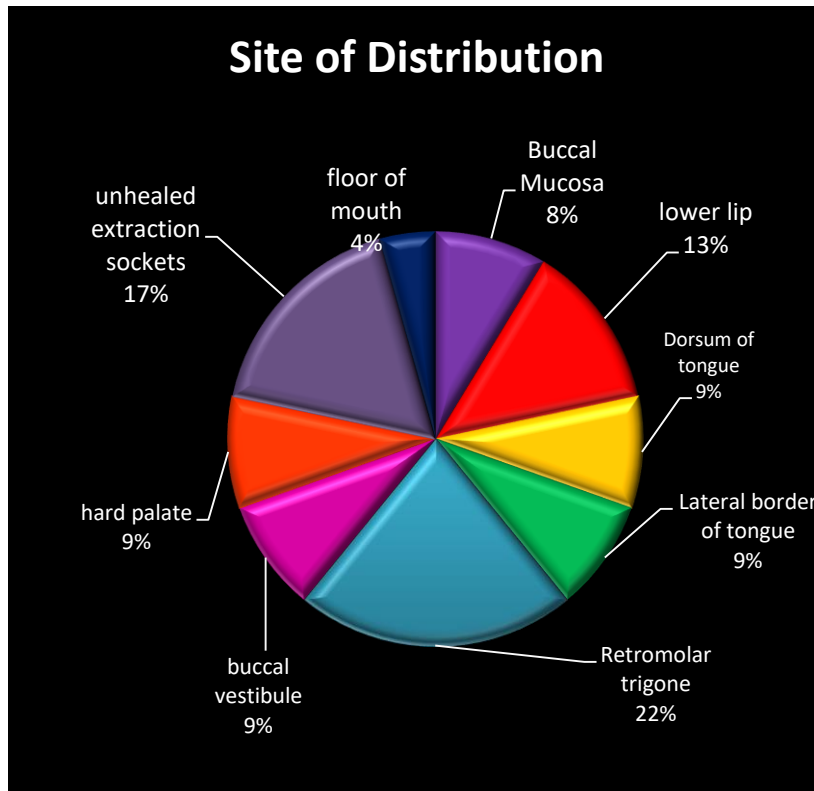
Patient No.	Year	Age	Sex	Duration of symptoms	Location	Differential diagnosis	Chest Radiograph	Type of TB
17	2012	49	F	1 years	Retromolar, Hard Palate	Verrucous Cell Carcinoma	Active	Secondary
18	2013	10	M	9 months	Left Submandibular LN	Chronic Ulcer	Old TB not active lesion	Secondary
19	2013	43	M	1 month	Right Unhealed extraction wound 37	Squamous Cell Carcinoma	N	Primary
20	2014	19	F	8 month	Unhealed extraction socket with Submental LN involvement	Squamous Cell carcinoma with lymphadenopathy	N	Primary
21	2014	69	F	1 year	Dorsum of tongue, Submandibular LN involvement	Lymphadenopathy	Active	Secondary

N = Normal; NA = not Available; M = Male, F= Female

**All patients are arranged as per chronological year*

Table 2. Showing symptoms associated with oral tuberculosis patients in order of frequency

Symptoms	No. of Patients
1. Ulceration	12
2. Swelling or mass	5
3. Cervical Lymphadenitis	5
4. Fever	9
5. Focal Pain	2
6. Non Healing Extraction Wound	4



Pie Chart 1. summarized the symptoms associated with oral tuberculosis patients

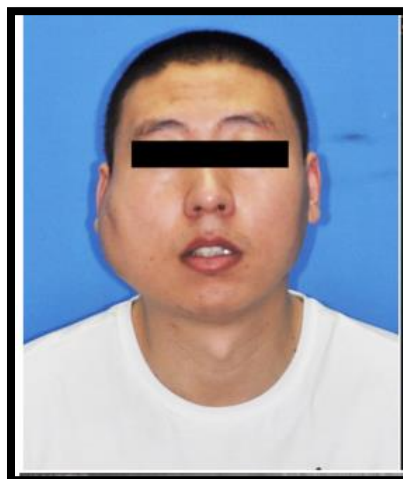

Fig. 1. Demonstrating the clinical picture of lesion

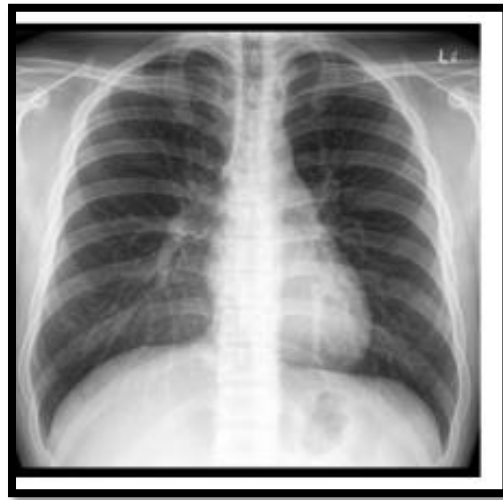

Fig. 2. Demonstrating the, radiological appearances of oral lesions

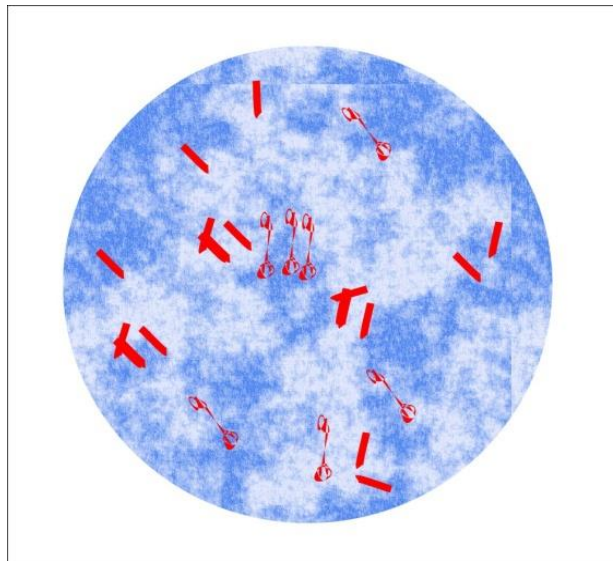


Fig. 3. Demonstrating the AFB staining histopathological appearances of oral lesions

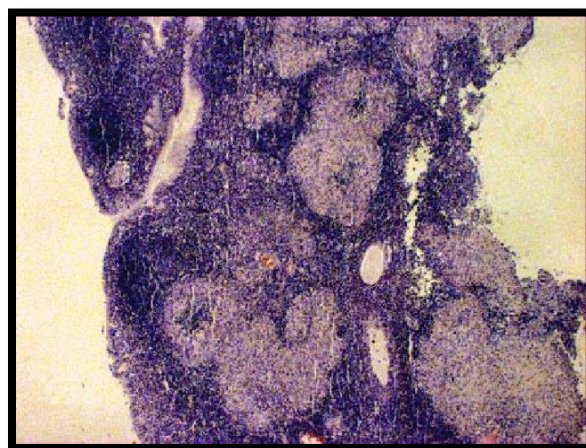


Fig. 4. Demonstrating the caseous necrosis on histopathological appearances of oral lesions

The most common manifestation was ulceration and swelling or mass ranging from 1 to 3 cm in diameter. None of these patients complains of malaise or weight loss, only few patients complains of fever or pain. The most common clinical symptom with TB in neck is swelling ranging from 0.5 to 3.5 cm in diameter There were 6 active pulmonary lesions and 1 patient with evidence of 1 old pulmonary TB were identified . In this Retrospective study there were 12 primary and 9 secondary TB lesions. Of all 12 Primary lesions, 8 cases were oral lesions while 4 cases had neck lesions associated with oral lesions. Out of 21 patients, 16 patients has the data related to positive sputum examination and 19 patients shows positive for Zeil-Neilson staining. All these patients have undergone anti-tubercular drugs regime ranging from 4 to 12 months only. Oral lesions have deliberately improve following proper and consistent medications. Only one patient have stopped the medication after 5 month following improved in his symptoms.

4. DISCUSSION

Tuberculosis oral lesions is extremely rare in occurrence and account for 0.5-1% as per various study. Tuberculosis of the oral cavity is an uncommon occurrence, may be because of an intact squamous epithelium of the oral mucosa which makes penetration difficult for the tuberculosis bacilli and provides protection against the infection. Although the mechanism of primary inoculation has not been definitely established as yet, it appears that the organisms are most likely to be carried in the sputum and that they enter the mucosal tissue through a small tear in the oral mucosa as a result of chronic irritation or inflammation, which may favour the localization of the organism. The local predisposing factors include poor hygiene, local trauma, dental extraction, leukoplakia, jaw fracture, cyst and abscess [4]. Primary oral TB lesions are extremely rare and are usually seen in children but they may also be seen in adults also. They typically involve the gingiva and are associated with regional lymphadenopathy. The secondary TB lesions are more frequent and involve the tongue, followed by the palate, lip, the buccal mucosa, the gingiva and the frenula. The oral manifestations of TB are seen as superficial ulcers, patches, indurated soft tissue lesions or even as lesions within the jaw, that may be in the form of TB osteomyelitis. The chronic ulcerative form is the most common among these oral lesions [5].

Head and neck tuberculosis (HNTB) is relatively rare, but can arise in many regions, including the lymph nodes, larynx, oral cavity and pharynx. When an ulcerating oral lesion coexists with palpable lymph nodes and is associated to risk factors like cigarette smoking, excessive alcohol consumption, and betel-quid chewing, it's clear that the clinical suspicion should remain focused on oral epithelial cell carcinoma, as noted within the current study. TB of the mouth frequently simulates cancerous lesions .like traumatic ulcers, aphthous ulcers, actinomycosis, syphilitic ulcer, or Wegener's granuloma. Therefore, if such a lesion is identified, especially in children, adolescents or females with no obvious exposure to risk factors for epithelial cell carcinoma, oral TB should be considered in the differential diagnosis. Only 3 patients in the current study had demonstrable radiographic evidence of pulmonary TB [6-8]. This is in contrast to 2 previous studies by Eng and colleagues [9] and Penfold and Revington [10] who reported radiographic evidence of pulmonary TB in 93% of patients with oral TB and 55% of patients with TB lymphadenitis, respectively. Extrapulmonary TB associated the neck was commonly found within the submental and submandibular lymph nodes also because the salivary glands. In our study, we found 3 cases as submental Lymphadenopathy while 4 cases with Submandibular Lymph node involvement. if cervical lymphadenitis is identified, we recommended that TB lymphadenitis should be considered and biopsy performed as soon as possible so that the correct diagnosis are often made and the correct therapy can be started without delay. Clinicians should be aware when diagnosing such lesions with a non healing tendency; tuberculosis should be considered in the differential diagnosis. It is vital for the clinicians to conduct a complete physical examination, including the signs and symptoms of pulmonary TB, with various diagnostic tests, as listed in and by performing a biopsy. A histopathological study is needed to exclude carcinomatous changes and to confirm the diagnosis of TB.

5. CONCLUSION

We conclude by stating that incidence of oral lesions in tuberculosis cases is very less, so each and every persistent and atypical oral lesion must be examined carefully to intercept and prevent the disease early. Intercepting the disease early will increase the morbidity and

mortality of the patients. Tuberculosis of the oral cavity is relatively rare and has largely become a forgotten diagnosis of oral lesions. Dental practitioners need to be aware that TB may occur in the oral cavity and that it should be considered in the differential diagnosis of any ulcerated, indurated, non healing lesion of the oral cavity, especially in the lower socioeconomic groups. In addition, efforts should be made to control oral TB by early detection and referral of the patient to a physician for proper management. Also, appropriate and effective infection control programs in dental surgery should be encouraged.

CONSENT

As per international standard or university standard, patients' written consent has been collected and preserved by the author(s).

ETHICAL APPROVAL

The ethical number was obtained from ethical clearance committee OS/2206/2020.

COMPETING INTERESTS

Authors have declared that no competing interests exist.

REFERENCES

1. Shamimul Hasan, Mohd. Abbas Khan: Tuberculosis - A common disease with uncommon oral features -Report of two cases with a detailed review of literature.
2. Pankaj Jain, Isha Jain. Oral Manifestations of Tuberculosis: Step towards Early Diagnosis. Journal of Clinical and Diagnostic Research. 2014;8(12):ZE18-ZE21
3. Kanwar Deep Singh N et al, Oral Tuberculosis. Journal of Clinical and Diagnostic Research. 2011;5(2):357-360.
4. Ito FA, de Andrade CR, Vargas PA, Jorge J, Lopes MA. Primary tuberculosis of the oral cavity. Oral Dis. 2005;11:50-3.
5. Mignogna MD, Muzio LL, Favia G, Ruoppo E, Sammartino G, Zarrelli C, et al. Oral tuberculosis: a clinical evaluation of 42 cases. Oral Dis. 2000;6:25-30.
6. Ewa Krawiecka, Elżbieta Szponar. Tuberculosis of the oral cavity: an uncommon but still a live issue. Postep Derm Alergol. 2015;XXXII(4):302-306.
7. Bahar S, Zeytinoglu M, Tuncay U, Unal T. Oral mucosal ulceration- a manifestation of previously undiagnosed pulmonary tuberculosis. JADA. 2004;135:336-340.
8. Ewa Krawiecka, Elżbieta Szponar. Tuberculosis of the oral cavity: An uncommon but still a live issue. Postep Derm Alergol. 2015;XXXII(4):302-306.
9. Eng HL, Lu SY, Yang CH, Chen WJ. Oral tuberculosis. Oral Surg Oral Med Oral Pathol Oral Radiol Endod. 1996; 81:415-20.
10. Penfold CN, Revington PJ. A review of 23 patients with tuberculosis of the head and neck. Br J Oral Maxillofac Surg. 1996; 34:508-10.

© 2021 Gawande et al.; This is an Open Access article distributed under the terms of the Creative Commons Attribution License (<http://creativecommons.org/licenses/by/4.0>), which permits unrestricted use, distribution, and reproduction in any medium, provided the original work is properly cited.

Peer-review history:

The peer review history for this paper can be accessed here:
<https://www.sdiarticle5.com/review-history/78623>